

DOI: <http://dx.doi.org/10.21123/bsj.2021.18.2.0210>

The Prevalence of Parasites in the Domestic Pigeons (*Columba livia domestica*) in Zakho City, Kurdistan-Iraq

Araz Ramadhan Issa^{1*}

Wijdan M.S. Mero¹
Masood Ahmed Hameed²

Dalia Loqman Hasan¹

¹Department of Biology, Faculty of Science, University of Zakho, Zakho/Iraq

²Dept. of Animal production, College of Agricultural Engineering Sciences, University of Duhok, Duhok/Iraq

Corresponding author: araz915@yahoo.com, wijdan2000@yahoo.com, Dalya_hasan21@yahoo.com.uk, masoudzaxov92@gmail.com

ORCID: <https://orcid.org/0000-0003-1828-7188>, <https://orcid.org/0000-0002-0439-4372>, <https://orcid.org/0000-0003-1409-4709>, <https://orcid.org/0000-0002-9271-3686>.

Received 3/6/2019, Accepted 16/2/2020, Published Online First 11/1/2021, Published 1/6/2021



This work is licensed under a [Creative Commons Attribution 4.0 International License](https://creativecommons.org/licenses/by/4.0/).

Abstract:

Pigeons have accompanied humans since ancient time because they are used as a source of food, pets, hobby, and religious symbols. Pigeons have shown high prevalence rate of infection with gastrointestinal helminths and protozoan. This study was conducted to evaluate the prevalence of parasitic infections in the domestic pigeon (*Columba livia domestica*) from October, 2017 to April, 2018, purchased from bird market of Zakho City, Kurdistan region. The samples were taken from 50 adult pigeons (28 males and 22 females). The birds were transferred to Parasitology Laboratory, Faculty of Science, Zakho University. In the laboratory, each bird was sacrificed and immediately the feather and skin of under wings, chest and the rest of the body was examined for ectoparasites. The collected ectoparasites were preserved in 70% alcohol for further study. The sacrificed birds were dissected and their intestine and contained were examined for the presence of parasites. The results revealed a total rate of 76% of infection with ectoparasites, which included three species of lice, namely: *Columbicola columbae* (56%), *Companulotes compar* (36%) and *Hohorstiella lata* (10%). Regarding helminths, cestodes were the only helminths found in this study with a rate of 16% (8/50). Three species of cestodes were recorded, they included: *Raillietina cesticillus* (14%), *Raillietina echinobothrida* (4%) and *Choanotaenia infundibulum* (2%). Further studies are required to evaluate the effect of the recovered parasites on this host and their transmission to other poultry flocks and human.

Keywords: Cestodes, Ectoparasites, Pigeon, Prevalence.

Introduction:

Pigeons belong to order Columbiformes, which are domesticated birds that can be found in almost every town and city around the globe except for the poles (1, 2). This bird has accompanied humans since ancient time, and has close communication with humans, since is used as a source of food, pets, hobby, and religious symbols and recently as a laboratory animal (3, 4). It feeds on food items, which include grains, earthworm, and insects (5). Like other domestic poultry, pigeons have shown high prevalence rate of infection with gastrointestinal helminths and protozoan (6). Pigeons are able to fly for far distances, they can carry many parasites such as fleas, ticks, mites, and other parasites (7, 8, 9). These parasites can survive under several environmental conditions and live in

the body, the skin and between the feathers of the birds (10). Pigeons have a major role in spreading of infection and transmission of zoonotic diseases for people such as Newcastle disease, cryptococcosis, coccidiosis, toxoplasmosis and salmonellosis as well as being a reservoir of many parasitic diseases for poultry and other economic birds such as, chickens and ducks (11, 12, 13). Also, the ectoparasites and endoparasites that cause morbidity and mortality in these birds produce some symptoms such as weakness, loss of weight, anemia diarrhea and even the death of the birds (14, 15). Endoparasites are the most important diseases occurring in poultry especially cestodes (16). Only one study has been performed in Duhok City on the prevalence of pigeon parasites (17). The aim of this

study was to determine the prevalence of parasites of the pigeons (*Columbia livia domestica*) in Zakho City, as there are no previous studies in this direction in this area.

Materials and Methods:

The study was conducted between October 2017 and April 2018 in Zakho City, Duhok Province, Kurdistan Region/ Iraq. Fifty adult domesticated pigeons from both sex (28 males and 22 females) were purchased from bird market to which birds from different parts of Zakho City are sold. The birds were transferred to the Parasitology laboratory in the Faculty of Science, Zakho University. In the laboratory after sacrificing the birds, each bird was kept in a polythene bag, the ectoparasites were collected after sacrificing the pigeon, in addition, the feather of the head, neck, under the wings, legs and cloaca of each bird was inspected to look for more ectoparasites. The obtained parasites were preserved in 70% ethanol then; later on, they were identified according to the identification keys (18, 19).

Postmortem Examination for Endoparasites

This was done after decapitation, the abdominal and thoracic cavity of each pigeon was opened, and this was followed by systemic autopsy examination which includes the esophagus to the gizzard, the small intestine (duodenum, jejunum and ileum), the caeca, and the ileo-caeco-colic junction to the cloaca. Each section was kept in a clean Petri-dish, then opened longitudinally and the contents were washed with phosphate buffer (pH 7.2-7.4), then passed through 100 μ m stainless steel sieve. The mucosa was scraped to collect the helminths embedded in the mucosal layer. Finally, the contents were examined under stereoscopic microscope and all of recovered helminths were counted. The recovered helminths were cestodes only (Fig. 1), each cestode before being fixed was measured and cut into various pieces, the scolex was placed between two cover slips while the proglottids were placed between two slides, tight with a thread, then fixed in 70% ethanol in fully labeled containers for further processing and identification.

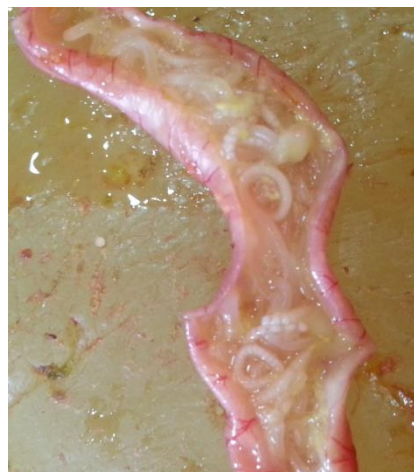

Figure 1. Cestodes adhered to the intestinal mucosa.

Staining and Identification of Cestodes

The fixed cestodes and proglottids were placed in descending alcohol series (50 and 30) then washed several times with tap water and then were stained with aceto-carmin stain. Following staining, they were passed through a series of ascending ethanol (30, 50, 70, 90 and 100 %) and cleared in xylol for 15-30 minutes depending upon the consistency of the material mounted in Canada balsam or DPX examined under light microscope at 10X magnification then identified according to dependent key (19).

Results and Discussion:

In this study only ectoparasites and cestodes were isolated from infected pigeons, other parasites were not found.

Ectoparasites: The total rate of infestation with ectoparasites was 76 % (38/50 of pigeons examined) some were infected with more than one species of parasites as shown in Table 1. The recorded ectoparasites were three species of lice which have been collected from different parts of the body (head, neck, under the wings, legs and cloaca), they included: *Columbicola columbae*, *Companulotes compar* and *Hohorstiella lata* (Fig. 2). The prevalence rate of infestation with ectoparasites reported in this study is much higher than the rate (6%) recorded by (17) in Duhok city. Slightly lower rates of infestation with different species of lice have been reported in Turkey [20], in Nigeria (21), in Tanzania (22) and in Bangladesh (23) which were 52, 60, 62 and 67%, respectively. While in Libya a higher rate (89%) of infestation with ectoparasites was reported (24).

The highest rate (56%) in this study was with *Columbicola columbae*, whereas, the two other lice species (*Companulotes compar* and *Hohorstiella lata*) were found at lower rates, 36% and 10%,

respectively. The rate of infestation with each species of lice recorded in the present study is higher than those recorded in Duhok which was 6% infestation with *Columbicola columbae* (17) and also in Bangladesh which was 21% (23). Studies performed in Spain (25), in Libya (24), in Iran (26, 10), in Colombia (27), in Bangladesh (28) and in Ukraine (29) recorded rates of 100%, 82%, 79.41%, 78.40%, 64%, 50% and 100%, respectively. Also Ukraine (29) recorded higher infestation rate of *Hohorstiella lata* and *Companulotes compar* (72.7 and 41.8%, respectively) than the rates of the present study. Lice cause damage by chewing feathers as they squeeze between the barbs of the feathers and they are more commonly seen in outdoor housed birds (30).

Regarding gender, the rate of infestation in males was higher than females (55.26% versus 44.74%). While in Nigeria (21) reported equal rates in both sexes. In a study in Turkey (20) a higher rate of infestation was reported in females than males (54.5% versus 48.9%). The higher rate in males is attributed to more susceptibility to infection than females and they are more affected by infestation and this could be due to behavioral differences, with one gender coming into contact with sources of infection more than the other. Furthermore, it has also been ascribed to the association between testosterone and the immune system, although the exact mechanism of action is unclear, but evidence suggests that testosterone has an immunosuppressive role which would hamper the elimination of the parasites (31).

Table 1. Prevalence of ectoparasites in pigeon (n=50).

Positive sample	%	Gender				Name of ectoparasites	No. of host infected	(%)
		Male	%	Female	%			
38/50	76	21/38	55.26	17/38	44.74	<i>Columbicola columbae</i>	28/50	56
						<i>Companulotes compar</i>	18/50	36
						<i>Hohorstiella lata</i>	5/50	10



A



B



C

Figure 2. Three species of lice recovered from infested pigeons: A- male of *Columbicola columbae*, B- *Companulotes compar* (female and male) and C- female of *Hohorstiella lata* (general view).

Table 2 highlights the rates of single and double infestations in the pigeon, in which 50% were single and 26% were double, with predominance of *Columbicola columbae* in single infestations and as well as in all of double infestations. Similarly (22) Morogoro (Tnzania) reported higher rates of single infestation and

infection in pigeons and attributed to a lesser susceptibility of pigeons to mixed infections in comparison with chickens. On the other hand, some studies recorded higher rates of double infections, such as (21) in Nigeria which reported 26.7% of double and only 3.3% of single infestations.

Table 2. Frequency of single and mixed infestations with ectoparasites in examined pigeons (n=50).

Type of infestation	Species recorded	Frequency	%
Single	<i>Columbicola columbae</i>	15/50	30
	<i>Companulotes compar</i>	7/50	14
	<i>Hohorstiella lata</i>	3/50	6
Double	<i>Columbicola columbae</i> + <i>Companulotes compar</i>	11/50	22
	<i>Columbicola columbae</i> + <i>Hohorstiella lata</i>	2/50	4
Total		38/50	76

Cestodes

The rate of infection with different species of cestodes is shown in Table 3, in which 8 out of 50 (16%) pigeons examined, were found infected by three species of cestodes. These cestodes inhabited the small intestine, which included: *Raillietina cesticillus* (Fig.3), *R. echinobothrida* (Fig.4) and *Choanotaenia infundibulum* (Fig.5). Higher rates of infection with cestodes in pigeons have been reported in Kurdistan and other parts of Iraq, such as, (17) in Duhok and (32) in Baghdad which were 22% and 17.14%, respectively. Much higher rates of cestodes infection have been reported in Diyala (33), in Babylon (34) and in AL-Dewaniya (35) which reported rates of 73.01%, 57.97% and 46.31%, respectively. Also, in Egypt, a rate of 30.9% was reported (36).

In this study, the highest (14%) rate of infection was with *R. cesticillus*, while both *R. echinobothrida* and *Choanotaenia infundibulum* were recorded at low rates (4% and 2%). Similarly (21) in Nigeria recorded high infection rate (26.7%) with *R. cesticillus*. Whereas, in a study in Duhok

and another one in Nigeria high rates of *R. tetragona* were recorded (22% and 27.1%) (17, 7) respectively. In Baghdad (32) and in Egypt (36), high rates were reported (17.14% and 17.7%) with *R. echinobothrida*. Most pigeons were infected with cestodes and 75% of cestodes were *Raillietina* spp. (37, 38). Cestodes cause severe histological changes in the host, they can cause lesions including congestion, inflammation, nodules formation in intestinal mucosa and pin point hemorrhages (39). Different species of cestodes cause severe destruction of villi, desquamation and degeneration of epithelial cells (40, 39).

With respect to gender, females showed a higher rate (62.5%) than males (37.5%). This finding is similar to the results obtained by (41) in Erbil, (34) in Babylon, (35) in AL-Diwaniya and (42) in Nigeria; in all these studies higher rates of infection were found in females. On the other hand, the present results disagree with a study performed in Diyala (33) and in Brazil (43) which reported high rate of infection in males.

Table 3. Prevalence of cestodes in Pigeon (n=50).

Positive sample	%	Gender				Name of cestodes	No. of host infected	%
		Male	%	Female	%			
8/50	16	3/8	37.5	5/8	62.5	<i>Raillietina cesticillus</i>	7/50	14
						<i>Raillietina echinobothrida</i>	2/50	4
						<i>Choanotaenia infundibulum</i>	1/50	2




Figure 3. *Raillietina cesticillus*, A: Scolex, B: Mature proglottid and C: Gravid proglottid using AmScope




Figure 4. *Raillietina echinobothrida*, A: Scolex, B: Mature proglottid and C: Gravid proglottid using AmScope

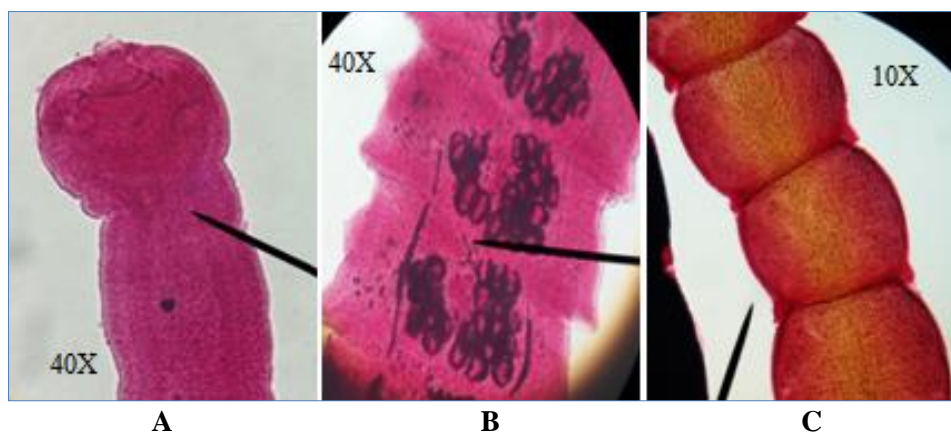


Figure 5. *Choanotaenia infundibulum*, A: Scolex, B: Mature proglottid and C: Gravid proglottid using AmScope

Table 4 shows the rate of mixed infection of cestodes in the pigeon. Single infection accounts for 12%, while double ones were recorded at low rate (4%). Similarly in Nigeria (7) and Iran (44) higher rates of single infection than double infections were recorded. The prevalence of cestodes in pigeon may

be attributed to the abundant presence of the intermediate hosts of these parasites; such as beetles, pill bugs, ants, earthworms and snails which form part of the diet of pigeons, which can easily infect the birds via their diet (5).

Table 4. Frequency of single and mixed infections of cestodes in examined pigeons (n=50).

Type of infection	Species of cestodes recovered	Frequency	%
Single infection	<i>Raillietina cesticillus</i>	5/50	10
	<i>Choanotaenia infundibulum</i>	1/50	2
Double infection	<i>Raillietina cesticillus</i> + <i>Raillietina echinobothrida</i>	2/50	4
Total		8/50	16

Conclusion:

It is concluded from this study that the examined pigeons showed high infestation rate (76%) with ectoparasites, included three species of lice. Regarding endoparasites only cestodes (three species) were recorded at a lower rate (16%). Some pigeons were infected with more than one species of parasites.

Authors' declaration:

- Conflicts of Interest: None.
- We hereby confirm that all the Figures and Tables in the manuscript are ours.
- The authors have signed an animal welfare statement.
- Ethical Clearance: The project was approved by the local ethical committee in University of Zakho.

References:

1. Cooper JE. A veterinary approach to pigeons. J. Small Anim. Pract. 1984; 25:505-516.
2. Marques SM, Quadros RM, Sailva CJ, Baldo M. Parasites of pigeons (*Columba livia*) in urban areas of Lages, Southern Brazil. Parasitol. Latino Amr., 2007; 62: 183-187.
3. Harlin RW. Pigeon the Veterinary clinics of North America. J. Small animals' practice. 1994; 24:157-173.
4. Sari B, Karatepe B, Karatepe M, Kara M. Parasites of domestic pigeon (*Columba livia domestica*) and wild (*Columba livia livia*) pigeons in Nigde, Turkey. Bull. Vet. Inst. Pulawy. 2008; 52: 551-554.
5. Adang KL. Some aspects of the biology of four columbid species in Zaria, Nigeria. Unpublished M. Sc. Thesis. Department of Biological Sciences, Ahmadu Bello University, Zaria, Nigeria. 1999.
6. Ghazi RR, Mansour NK, Bilqees FM. Palluterinakarachiensis sp. n. (Cestoda: Anaplocephalidae) from the wild pigeon *Columba livia* Gmelin. Turk. J. Zool., 2002; 26: 27-30.
7. Adang KL, Oniye SJ, Ezealor AU, Abduand PA, Ajanusi OJ. Ectoparasites of domesticated pigeon (*Columba livia domestica*, Linnaeus). Res. J. Parasitol., 2008; 3:79-84.
8. Rehman R. A study on the prevalence of *Ascaridiagalli* and the effects of experimental infection on various blood parameters and body weight in the chicken. MSc. (Hons) Thesis, University of Agriculture (CVS), Faisalabad-Pakistan. 1993.
9. Opara MN, Ogbuwu IP, Iwuji CT, Njokua L, Ihesie EK, Etuka IF. Blood characteristics, microbial and gastrointestinal parasites of street pigeons in Owerri Imo State, Nigeria. J. Anim. Sci. 2012; 1: 14-21.

10. Jahantigh M, Esmailzadeh Dizaji R, Teymoori Y. Prevalence of external parasites of pigeon in Zabal, southeast of Iran. *J. Parasit. Dis.* 2016; 40(4): 1548-1551.
11. Kaminjolo JS, Tikasingh ES, Ferdinand GAA. Parasites of the common pigeon (*Columba livia*) from the environs of Port of Spain, Trinidad. *Bull. Anim. Health Prod. Afr.*, 1988; 36:194-195.
12. Patel PV, Patel AI, Sahu RK, Vyas R. Prevalence of gastrointestinal parasites in captive birds of Gujarat zoos. *Zoos' print J.*, 2000; 15(7): 295-296.
13. Piaseki T. Evaluation of urban pigeon (*Columba livia furbana*) health status in relation to their threat to human. *Medycyna Weterynaryjna.* 2006; 62:531-535.
14. Soulsby E.J.L. *Helminths, Arthropods and Protozoans of Domesticated Animals*, 7th edition. London, Bailliere, Tindall. 1982.
15. Mohammad HR, Saeid F, Ehsan NA, Mohammad MD and Hadi RS. A Survey of Parasites of Domestic Pigeons (*Columba livia domestica*) in South Khorasan, Iran, *Vet. Res.*, 2011; 4(1): 18-23.
16. Dranzoa C, Ocaido M, Katete P. The ecto, gastrointestinal and haemo- parasites of live pigeons (*Columba livia*) in Kampala, Uganda. *Avian Path.*, 1999; 28: 119-124.
17. Omer LT, Abdulla MA, Morad DA. Detection of parasitic infections and their pathological changes in wild pigeons in Duhok province; AL-Qadisiya J. of *Vet. Med. Sci.*, 2015; 14 (2):74-77.
18. Beck JW, Davies J. *Medical parasitology*. Third edition. St. Louis, C.V. Mosby. 1981; Pages: 376.
19. Soulsby E.J. *Helminths, Arthropods and Protozoa of Domesticated Animals*. 7th ed. London: Bailliere Tindall. 1986; pp:211-230.
20. El macioglu S, Yaman M, Zerek A, Akkücüük Ş, Karagöz M, Eedem I. Ectoparasites of Domestic pigeons (*Colomba livia domestica*) in Antakya Region, Turkey. *Turkish J of Vet. Res.* 2018; 2(2): 23-27.
21. Adang KL, Oniye SJ, Ezealor AU, Abdu PA, Ajanusi OJ, Yoriyo KP. Ectoparasites and Intestinal Helminthes of speckled pigeon (*Columba guinea hartlaub and finsch 1870*) in Zaria, Nigeria. *Sci. World J.* 2009; 4 (2):1-5.
22. Msolle PLM, Muhairwa AP, Chiwanga GH, Kassuku AA. A study of ecto- and endo-parasites of domestic pigeons in Morogoro Municipality, Tanzania; *Afr. J. Agric. Res.* 2010; Vol. 5 (3): 264-267.
23. Ghosh KK, Islam MS, Sikder S, Das S, Chowdhury S, Abdul Alim M. Prevalence of Ecto and Gastrointestinal Parasitic Infections of Pigeon at Chittagong Metropolitan Area, Bangladesh, *J. of Adv. Parasitol.* 2014; 1(1): 9-11.
24. Alkharigy FA, El Naas As, El Maghrbi AA. Survey of parasites in domestic pigeons (*Columba livia*) in Tripoli, Libya. *Open Vet. J.*, 2018; 8(4): 360-366.
25. Foronda P, Valladares B, Rvera-medina JA, Figueruelo E, Abreu N, Casanova JC. Parasites of *Columba livia* (aves: columbiformes) in tenerife (Canary Islands) and their role in the conservation biology of the laurel pigeons; *PARASITE J.* 2004; 11: 311 – 316.
26. Radfar MH, Fathi S, Asl EN, Dehagh MM, Srghinsara HR. A survey of parasites of domestic pigeons (*Columba livia domestica*) in south Khorasan, Iran. *Vet. Res.* 2011; 4(1): 18-23.
27. Perez-Garcia J, Monsalve-Arcila D, Marquez-villgas C. Presencia de parasitos y enterobacteria senpalomasferates (*Columba livia*) en areas urbanas en Enrigado, Colombia. *Rer. Fas. Na. salud Publica.* 2015; 33(3); 370-376.
28. Musa S, Afroz SD, Khanum H. Occurrence of ecto- and endo parasites in pigeon (*Columba livia Linn.*); *Univ. j. zool. Rajshahi Univ.* 2011; 30: 73-75.
29. Kolomak IO, Kruchynenko OV. Bird lice (*mallophaga, philopteridae, menoponidae*) of domestic pigeons on specialized pigeon breeding Farms in Poltava. *Vestnik zoologii*, 2017; 51(6):487–492
30. Mitchell MA, Tully TN. *Veterinary Technician's Guide to Exotic Animal Care*, 2nd ed., Lakewood, Colo., USA. 2012.
31. Hurd H. Males have higher parasite burdens than females. Can they cope. 2017. (<https://blogs.biomedcentral.com/bugbitten/2017/05/05/males-higher-parasite-burdens-females-can-cope/>).
32. Al-Marsomy WA, Al-Hamadaani HS. Association of Cestoda *Raillietina echinobothrida* in Rock Pigeon *Columba livia* from Baghdad city of Iraq. *Baghdad Sci. J.* 2016; 13(3): 463-468.
33. Al-Bayati NY. A study on pigeons (*Columba livia domestica*) cestodes infection in diyala province. *D. A. S. J.* 2011; 3(2): 1 – 12.
34. Al-Rammahi HM, AL-Hasnawy MH, Athmar K, Abbas AK. Concurrent Infection of Cestodes with Trichomoniasis in Domestic and Wild Columbides Birds in Babylon Province. *The Iraqi. J. Vet. Med.*, 2013; 37(2): 192-198.
35. Abed AA, Naji HA, Rhyaf AG. Investigation study of some parasites infected domestic pigeon (*Columba livia domestica*) in Al-Dewaniya city. *IOSR J. Pharm. & Biol. Sci.*, 2014; 9: 13-20.
36. Nagwa EA, Loubna MA, EL-Madawy RS, Toulan EI. Studies on helminthes of poultry in Gharbia Governorate. *Benha Vet. Med. J.* 2013; 25(2):139-144.
37. Kumaran V, Kunjan PN, Nadakal MA. New species from pigeon. *JPN J parasitol*, 1981; 30(3); 241–244.
38. Mushi EZ, Binta MG, Chab RG, Debele NR, Panzirah R. Helminth Parasites of domestic Pigeons (*Columba livia domestica*) in sebele, Gaborone, Botswana. *Onderstepoort J. vet. Res.*, 2000; 67(1):75-76.
39. Nisar S, Farhanullah Khan M, Aly Khan M, Arshad A, Mehboob U, Raza A. Histopathological changes of intestine of pigeon (*Columba livia*) artificially infected with *C. digonopora* and *C. cuneata*. *Int. j. fauna biol. stud.* 2015; 2 (3): 36-39.
40. Padhi BC, Misra SC, Panda DN. Pathology of helminthiasis in Desi fowls. Cestode infection. *Ind. J. Anim. Hlth.*, 1986; 25:127–131.
41. Al-Barwari S, Saeed I. The Parasitic Communities of the Rock Pigeon *Columba livia* from Iraq:

- Component and Importance. *Turkiye Parazitoloj Derg*; 2012; (36): 232-239.
42. Laku CB, Onwuteaka JN, Amuzie CC. Ecto-parasites and intestinal helminth community of domesticated pigeons (*Columba livia*) of Trans-Amadi Abattoir, part Harcourt, Nigeria. *J. Gastroenterol. Forecast*. 2018 Jul; 1: 1-3.
43. Vaz FF, Da Silva LAF, Ferreira VL, Da Sliva RJ, Raso TF. Gastrointestinal helminthes of two populations of wild pigeons (*Columba livia*) in Brazil. *Braz. J. Vet. Parasitol., Jaboticabal.*, 2017; 26(4): 446-450.
44. Khezerpour A, Naem S. Investigation on Parasitic Helminthes of Gastrointestinal, Liver and Lung of Domestic Pigeons (*Columba livia*) in Urmia, Iran. *Int. J. Livest. Res.*, 2013; 3(3): 35-41.

انتشار العدوى الطفيلية في الحمام المنزلي (*Columba livia domestica*) في مدينة زاخو، كردستان – العراق

اراز رمضان عيسى^{1*} وجدان محمد صالح ميرو¹ داليا لقمان حسن¹ مسعود احمد حميد²

¹قسم علوم الحياة، فاكولتي العلوم، جامعة زاخو، زاخو، العراق
²قسم الإنتاج الحيواني، كلية العلوم الهندسية الزراعية، جامعة دهوك، دهوك، العراق

الخلاصة:

لقد اقترن تواجد الحمام الأليف منذ الأزل مع الإنسان، حيث تم استخدامه كمصدر للطعام وحيوان داجن وكهواية ورمز ديني. في هذه الدراسة وجدت نسبة مرتفعة من الإصابة بالطفيليات الخارجية ونسبة اقل بالديدان الشريطية فقط في الطيور المستخدمة. أجريت هذه الدراسة لتقييم مدى انتشار الطفيليات التي تصيب الحمام المنزلي (*Columba livia*) من تشرين الأول 2017 إلى نيسان 2018، الذي تم شرائه من سوق الطيور في مدينة زاخو، إقليم كردستان. تم أخذ العينات من 50 حمام بالغ (28 ذكر و 22 أنثى). تم نقل الطيور إلى مختبر علم الطفيليات، فاكولتي العلوم، جامعة زاخو. في المختبر تم فحص الريش لكل طير ثم تم تشريحها وعلى الفور تم فحص الريش والجلد تحت الأجنحة، الصدر، للبحث عن الطفيليات الخارجية. ثم جمعت الطفيليات الخارجية وحفظت في 70٪ من الكحول لإجراء المزيد من الدراسة. تم تشريح الطيور التي تم ذبحها وفحصت الأمعاء للبحث عن وجود الطفيليات الداخلية. أظهرت النتائج عن معدل إجمالي قدره 76٪ (50/38) من العدوى بالطفيليات الخارجية، والتي تضمنت 3 أنواع من القمل، وهي: *Columbicola columbae* (56٪)، *Companulotes compar* (36٪) و *Hohorstiella lata* (10٪). فيما يتعلق بالديدان الشريطية، كانت الديدان الشريطية هي الديدان الوحيدة الموجودة في هذه الدراسة، بمعدل 16٪ (50/8). تم تسجيل ثلاثة أنواع من الديدان الشريطية وهي: *Raillietina cestocillus* (14٪)، *R. echinobothrida* (4٪) و *Choanotaenia infundibulum* (2٪). هناك الحاجة إلى المزيد من الدراسات في هذا المجال لتقييم التأثير المرضي للطفيليات التي يتم عزلها من هذا الحيوان الداجن و إمكانية انتقالها إلى بقية الطيور أو الإنسان.

الكلمات المفتاحية: حمام، الطفيليات الخارجية، الديدان الشريطية، انتشار.