

Effects of Ethanol on the Hippocampus of Rat Brain

Nadheer, A.Fazaa *

Date of acceptance 9/11/2005

Summary

Ten albino male rats were orally treated daily with 20% and 30% ethanol (5 ml) for 30 days. Treatment with 30% ethanol caused degeneration of hippocampus cells accompanied by decrease in cells density and tissue dissociation. Treatment with 20% ethanol resulted in congestion of blood within the blood vessels located in the damaged tissue, fatty changes and microglial aggregation around the damaged neurons. In conclusion, and according to the protocol employed in the present study, these concentrations of ethanol caused severe damaging effects to the hippocampal formation in rats brain. Several explanations for these effects were discussed.

Introduction

Long-term alcohol consumption is known to produce huge neuroanatomical changes in the brain of animals (1) and human (2). More specifically, a massive neuronal loss has been reported in the cerebellum (3,4) basal forebrain and hippocampal formation (5,6,7) of rodents following long periods of alcohol intake. The hippocampal formation has received considerable attention, since mnemonic function deficit was found to be identical in chronic alcoholics and in patient with hippocampal lesion (8). Thus, the behavioral abnormalities that are seen in subjects after chronic alcohol consumption (CAC) are thought to be associated with the alcohol – induced neurogenerative alteration, basically in the hippocampal formation (9), which is known to play an important role in memory tasks (10). Studies of different levels were performed to shed the light on the particular sensitivity of hippocampal formation to CAC. Morphometric techniques were used to show that all main hippocampal cell populations are vulnerable to ethanol (11,12). At the ultra structural level, a striking reduction has been demonstrated in the

number of synapses between Mossy fibers and apical dendrites of CA3 pyramidal neurons (13). Also, biochemical studies have found that prolonged alcohol ingestion induced a progressive deposition of lipofuscin (12), a striking indicator of degeneration in the nervous tissues. Most of the aforementioned studies have used long periods of alcohol continuous feeding that extended in some studies for up to 18 months (5,11,12). In fact, this was primarily due to the observation that the morphological changes in the brain of alcohol – fed rats were dependent upon the length of alcohol exposure (14). However, in a previous study on the effects of ethanol on different areas of rat's brain, other than the hippocampus formation, it was found marked signs of neuronal degeneration after oral administration of ethanol for no longer than 30 days (3). Using the latter model, and the histopathological technique as a criterion for ethanol effects on hippocampal formation in rats, the present attempted study to add a new complementary step to the study of such critical and life threatening problem.

* Department of Biology, College of science for women,
Baghdad University

Materials and Methods

Animals and Treatment

Fifteen Male albino rats *Rattus norvegicus* obtained from the college of medicin, university of al-nahrin weighing 350gm were used in the present study. Animals were housed 5 per cage, and exposed to a 14: 10h light: dark cycle under room temperature (25-30) c°. Standard laboratory chow and water were provided *ad libitum* to both controls (n=5) and alcohol-treated (n=10) groups. Alcohol- treated rats were orally dosed with 20 and 30% ethanol solution (5ml/dose /day) for 30 days. All animals were maintained on their respective diets for 30 days.

Tissue preparation

The animals were anesthetized with chloroform (12); and then the brains were removed from the skulls and separated by a midsagittal cut. The brain hemispheres were fixed with 10% formalin for 24h (16), washed with running tap water for 30 minutes to remove the fixative and then dehydrized through a series 70%, 80%, 90%, 95%, 100%, of alcohol concentrations (2h for each concentration) (16). Samples were cleared with xylen for 20 min. and embedded with paraffin wax. Rotary microtome was used to prepare 7/ μ m-thick serial sections, which were mounted on glass slides and then stained with Delafield's haematoxylin – eosin and methylen blue – eosin steins (3). Finally, specimens were examined under light microscope to evaluate the histopathological effects of ethanol on rat brain.

Results

The results showed that the chronic ethanol treatment caused a series of damaging effects on the cellularity and histology of the hippocampus. At the

cellular level, degeneration was prominent in the cells of the hippocampus (Figure 1) as a result of treatment with 30% ethanol. This was accompanied by a decrease in the cellularity (cell density) and dissociation in the tissue of the hippocampus (Figure 2), as compared to the normal tissue (Figure 3). Aggregations of microglial cells were found around the damaged cells (Figure 4). After treatment with 20% ethanol, blood vessels in the damaged area were characterized by the congestion of blood within these vessels (Figure 5). In addition, deposits of fat in the form of fatty chains were also present in the affected tissues as a result of treatment with ethanol (Figure 6)




Figure (1) sagittal sections of rat brain after ethanol treatment (30%) showing degeneration in the cells of hippocampus (H&E) 400 x .




Figure (2) Sagittal section of rat brain after ethanol treatment (30%) showing dissociation (B) in the tissue of hippocampus (M&E) 200x.

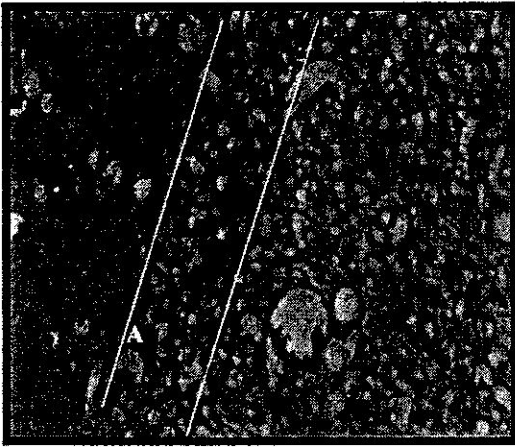


Figure 3 Sagittal section of normal tissue of hippocampus M E 200X .




Figure 4 sagittal section of rat brain showing aggregation of microglial cells around the damaged neurons in the tissue of hippocampus after the ethanol treatment 30 % H &E 200X .




Figure 5 sagittal section of rat brain showing congestion of blood in the hippocampal tissue after ethanol treatment 20 % H&E 100_x

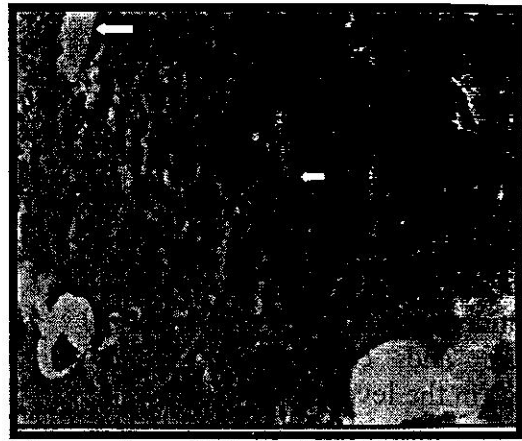

Figure 6 sagittal section of rat brain showing fatty changes after ethanol treatment 20 % H&E 200X .

Discussion

The present study demonstrated that oral treatments with ethanol (20% and 30%) for 30 days caused neurotoxic effects to the hippocampal formation in rats. These results are consistent with the previous studies that have reported a critical involvement of the hippocampal formation in the CNS defects caused by CAC (7). The present results are also in agreement with the reports that have shown that CAC causes reduction in the density of hippocampal granular cells and pyramidal cells (1). In the same context, Cadett-Liete and his colleagues have showed that granule cell loss was progressive (5) and not impeded even after prolonged periods of alcohol withdrawal (6). The same research group has reinforced the former observation by reporting a significant loss of CA3 pyramidal cells, a reduction in the thickness of the pyramidal cell layer, and a significant decrease in the MF-CA3 synapses following CAC (5).

To explain these effects there are several possible mechanisms that might account for these damaging effects of ethanol upon the hippocampal formation. Firstly, Brooks¹⁷ has suggested that CAC

results in elevated levels of reactive oxygen species (ROS) and lipid peroxidation (LP) in addition to acetaldehyde (AcH), which are resulted from ethanol oxidation in the brain. The accumulation of such products leads to inhibition of the nucleotide excision repair (NER) pathway and consequently to an increase in the levels of damaged DNA and an inhibition in the gene expression in the neurons (17). As a result, nerve cell death will occur either due to the reduction in the levels of basic gene products, proteins, or due to the programmed cell death, apoptosis (18).

Secondly, a direct effect for ethanol has been suggested both on the receptors of chemical transmitters and on the ion channels located on the neuronal plasma membrane. In this regard, it has been demonstrated that CAC inhibits γ -aminobutyric acid (GABA) receptors through its effect on Cl ion channels (19). In addition, acute alcohol intake was proved to inhibit the glutamate receptors and N-methyl-D-aspartate (NMDA) receptors (20).

A third possible explanation based on a series of investigations that showed that CAC results in a significant reduction in the levels of total sialic acid (TSA) and lipid bound sialic acid (LBSA) both in the serum and brain of ethanol treated animals (3,21). In this context, it has been suggested that ethanol when reaches the surface of neuronal cell membrane, replaces the water bound to the SA and anchors in the lipid bilayer. This leads to a change in the conformation of receptor proteins, making SA more susceptible to the action of sialidase that removes SA from the polysaccharide chain (21). Removal of SA by ethanol eventually leads to inhibition of the activities of chemical transmission receptors and ion channels impedance of nervous

impulse flow, and weakening of the functional connections among neurons. This might results in nerve cell death either due to accumulation of toxic metabolic products or to apoptosis (3).

References

- 1- Walker, D.W.; Hunter, B.E. and Abraham, W. C. (1981). Neuroanatomical and Functional deficits subsequent to chronic ethanol administration in animals, *Alcoholism: Clin.ExpRes.* 5: 267 – 282.
- 2- Chrness, M.E. (1993). Brain lesions in alcoholics. *Alcohol Clin. Exp. Res.*, 17: 2-11.
- 3- Nadheer,A.Fazaa , (2001). The Effect of Ethanol on the level of Sialic Acid in the Brain and Serum of Albino Male Rats. M.sc. thesis, University of Baghdad, College education (Ibn – Al- Haitham).
- 4- Krill, J. J. and Halliday, G. M. (1999). Brain shrinkage in Alcoholics: A Decade on and what have we Learned?. *Neurobiology*, 58: 381-387.
- 5- Cadete- Liete, A.; Alves, M.C.;Tavares ;,M.A. and Barbosa , M.P.(1990).Effects of chronic Alcohol intake and withdrawal on the prefrontal neurons and synapses. *Alcohol*, 7: 145-152.
- 6- Cadete – Leite, A.; Andrade, J.P.; Sousa, N.; Silva,A.R.(1995). Effects of chronic Alcohol consumption on the cholinergic innervations of the rat hippocampal formation as revealed by choline acetyltransferase. *Immunocytochemistry. Neuroscience*, 64(2) 357-374.

- 7- Paula-Barbosa, M.; Brandao, F.; Andrada, J.; Madeira, M.D. and Cadete-Leite, A. (1991). The effects of piracetam on lipofucin of the rat cerebellar and hippocampal neurons after long-term alcohol treatment and withdrawal: A quantitative study. *Alcoholism, Clin. Exp. Res.*, 15 (5): 834-838.
- 8- Buttres, n.; cermak, ; Montgomery, k. and Adinolfi, a. (1977). Some comparisons of the memory and visuoperceptive deficits of chronic alcoholics and patients with Korsakoff disease. *Alcoholism, Clin. Exp. Res.* 1: 73-80.
- 9- Walker, D.W.; Heaton, M.B.; LEE, N.; Kinng, M. and Hunter, B.E. (1993). Effect of chronic ethanol on the septohippocampal system: A role for neurotrophic factors. *Alcohol, Clin. Exp. Res.*, 17: 12-18.
- 10- Berry, R.B. and Mathews, D.B. (2004). Acute ethanol administration selectively impairs spatial memory in C57BL/6J mice. *Alcohol*, 32(1): 9-18.
- 11- Andrade, J.P.; Fernando, P.M.; Madeira, M.D.; Paula-Barbosa, M.M.; and Zimmer, J. (1992). Effects of chronic alcohol consumption and withdrawal on the Somatostatin-immunoreactive neurons of the rat hippocampal dentate hilus. *Hippocampus*: 2: 65-72.
- 12- Cadete-leite, A.; Tavares, M.A.; Uylings, H.B. and Paula-Barbosa, M.M. (1988). Granule cell loss and dendritic regrowth in the hippocampal dentate gyrus of the rat after chronic alcohol consumption. *Brain Res.* 437: 1-14.
- 13- Cadete – Leite, A.; Tavares, M.A. and Volk, B. (1989). Hippocampal mossy fiber-CA3 Synapses after chronic consumption and withdrawal. *Alcohol*, 6: 303-310.
- 14- Tavares, M.A. and Paula-Barbosa, M.M. (1984). Remodeling of the cerebellar glomeruli after long-term alcohol consumption in adult rat. *Brain Res.*, 309: 217-227.
- 15- Bohnsky, F. (1986). Photo manual and Dissection guide of the rat. Avery publishing group inc., USA, 129-138.
- 16- Humason, G. L. (1972). *Animal Tissue Techniques*. 3rd. ed., W. H. Freeman and company San Francisco.
- 17- Brooks, P. J. (2000). Brain atrophy and neuronal loss in alcoholism: a role for DNA Damage. *Neurochem. Inter.* 37: 403-412.
- 18- Ljungman, M.; Zhang, F.; Chen, F.; Rainbow, A. J. & McKay, B. C. (1999). Inhibition of RNA polymerase II as a trigger for the P53 response. *Oncogene*, 18: 583-59.
- 19- Smothers, C.; Mrotek, C. & Lovinger, D. M. (1997). Chronic ethanol exposure leads to selective enhancement of N-methyl-D-aspartate receptor function in cultured hippocampal neurons. *J. pharmacol. Exp. Ther.*, 283: 1214-1222.
- 20- Masorero, E.; Frattini, P.; Favalli, ;; Rozza, A. (2001). Effect of acute Alcohol on

ischemia-induced glutamate
release and brain damage.
Alcohol, 22: 173-177.
21- Klemm, W. R. (1990).
Dehdration: A new

Alcohol theory. Alcohol, 7:
49-59.

تأثير الايثانول في منطقة قرن امون Hippocampus في دماغ الجرذ

نظير عبود فزع *

* المدرس المساعد ، قسم علوم الحياة - كلية العلوم للبنات - جامعة بغداد

الخلاصة:-

تم تجريب عشرة من ذكور الجرذ البيض عن طريق الفم بتركيز 20% و 30% من الكحول الاتلي يوميا وبحجم جرعة 5 مل و لمدة 30 يوم . اظهرت نتائج المعاملة بتركيز 30% حصول تنكس واضح في الخلايا العصبية لقرن امون يرافقه تفكك في هذا النسيج ، كما و بينت نتائج المعاملة بالايثانول تركيز 20% وجود احتقان في الدم داخل الاوعية الدموية الواقعة في النسيج المتضرر فضلا عن وجود التغيرات الدهنية وتجمع خلايا الدبق الدقيق حول الخلايا المتضررة. نستنتج طبقا للطريقة المستخدمة في هذه الدراسة بان تراكيز الكحول المستخدمة تؤدي الى تاثيرات ضارة وشديدة لمنطقة قرن امون في دماغ الجرذ.