

He-Ne Laser Irradiation Encourages reparative processes After cartilage loss in New Zealand rabbits

*Ibtisam K.A.Ali**

Date of acceptance 25/6/2007

Abstract

Many therapeutic methods used to encourage reparative processes of cartilage and accelerate their healing such as drugs, magneto-laser and so on. Twenty four adult New Zealand rabbits used in this study. They were divided in to two groups; control and treated with He –Ne laser. A square skin flap done on the medial aspect of both auricles followed by peeling a square piece of cartilage from the auricle then the flaps sutured. The site of the operation in the rabbits of the treated group were irradiated with He –Ne laser 5mw power for seven days began after the operation directly. 3 rabbits from each group used for collection of specimens for histopathological examination at the 1, 2, 4 & 6 weeks post the operation. Significantly well developed cartilage growth, chondroblasts and chondrocytes invade the area of the operation. High increase in the thickness of connective tissue in the same area contain mainly collagen fibers and lesser amount of elastic fibers. He –Ne laser irradiation raised the mitotic activity of the cartilage cells, activated the reproduction processes in addition to the intra and extra regenerative repair

Introduction

The cartilage found in the external ear is of fibro elastic nature which consists of typical chondrocytes and yellow elastic fibers provided the matrix except around the lacunae.

Cartilages are known as avascular tissues, because most of their cells are far from exchange vessels which are located mostly in the perichondrium while the nutrients diffuse to the chondrocytes depending on the difference between the concentrations, (1).

For these reasons cartilages have little ability for regeneration and it is well known that they heal by forming fibrous tissue scars, (2).

Ear surgery can replace ears lost due to injury or correct ear problems such as awkward folding, unusual smallness or absence of natural folds and curves, (3).

The external auricle has a high potential for injury due to its exposed and unprotected position alongside the head. A retrospective study looking at hospital

records in auricular injury cases revealed that human bites constitute the most common cause of injury (42%). This was followed by falls (20%), automobile accidents (16%), and dog bites (14%). The most common injury observed was incomplete amputation of the ear, usually helical rim tissue loss. Untreated open auricular injuries invariably result in infection, ensuing deformities, and further tissue loss, (4).

The therapeutic effect of laser therapy in wound healing had been identified so that a better knowledge about the mechanism of tissue repair using light energy obtained in the areas of skin, muscle, ligaments, nerves, bones and cartilage which respond to doses of light with wavelengths range between 600-1000nm, but the amount of energy absorbed varied from one tissue to another even when the wave length remain constant, (5).

A team of authors explained the enhancing role of laser radiation of blue

*College of Nursing – University of Baghdad.

and red regions on the early regenerative processes, (6). Many changes occur on the sub cellular levels for example acceleration of collagen and its precursors, (7).

This is very important for the healing process especially when known that the collagen form about 50% of the dry weight of the inter cellular matrix, (1).

Materials & Methods

Twenty four rabbits were used in this study. They were distributed into two groups, group A as a control and group B as a treated irradiated with He – Ne laser

General anesthesia induced using a mixture of Ketamine Hydrochloride and Xylazin administered intramuscularly, (8).

The surgical field prepared by rubbing the skin of the medial aspect of both auricles with povidon iodine 0.75% solution. Then three sided square skin flaps done with 4 mm / axis length on each side. The yellow cartilage exposed and square incisions with 3 mm / axis done and peeled out. The skin flap sutured with simple interrupted stitches using 4-0 silk. Then the animals injected with systemic antibiotics; penicillin 1000 iu/kg. B.W. and streptomycin 10mg/kg. B.W. i/m for 3 days after the operation.

The site of the operation in the treated group irradiated with a He – Ne laser 632,8 nm wavelength, 5mW power applied directly after the operation and daily for 7 days after that with 10 minutes / session, by direct contact of the beam source on the line of the incision. Three animals of each group were anaesthetized and specimens collected from the edges of the holes left after peeling of the cartilage to be consisted of both original and transmitted tissues.

The specimens sent for histopathological examination using Ordinary Hematoxylin & Eosin stain at the weeks 1,2, 4 & 6 post the operation. The dimensions of the square holes left after

peeling the cartilage measured using a very small metal ruler at the ends of the same periods to assess the advance of the healing processes. The values obtained from measuring of the holes were estimated statistically using ANOVA analysis of variation.

Results

Specimens collected from the control group one week post operation showed high infiltration of inflammatory cells (neutrophils) in the area of operation with punctate hemorrhages. While specimens collected at the same period from the group treated He-Ne with laser showed lesser amount of damaged tissue and punctate hemorrhages with infiltration of neutrophils in the area of operation. The connective tissue matrix, which contains mainly elastic fibers and lesser amount of collagen fibers appeared. Chondroblasts and chondrocytes invade the site of the Operation they appeared few in numbers.

Specimens collected from the animals of the control group two Weeks post operation revealed infiltration of inflammatory cells (neutrophils), damaged blood vessels appeared lesser amount.

Chondroblasts and chondrocytes numerous in number, the mitosis Division take place at the area of operation with thin layer of elastic and collagen fibers at the same area. For the same period the animals of the treated group showed chondroblasts and chondrocytes high in numbers, mitotic divisions take place at the area of the operation. Chondrocytes found in small clusters, each cluster represents a group of cell produced by mitotic division.

After four weeks of the operation samples collected from the control group showed just few inflammatory cells. Chondroblasts, chondrocytes and connective tissue also seen. The area of operation contain elastic fibers with little amount of collagen fibers. The treated group for the same period revealed no

signs of bleeding and inflammation in the area of operation. There is an increase in the cartilage growth in the middle of the mass so that chondrocytes appeared in the lacuna ,there is isogenic groups could be seen (Fig1), actively synthesized matrix material showed increase in its growth also (increase in thickness)containing mainly elastic fibers and lesser amount of collagen fibers.

Samples collected after six weeks of the operation in the treated group revealed presence of chondroblasts and chondrocytes in their lacunae. Connective tissue showed high increase in the thickness consist mainly elastic fibers and

lesser amount of collagen fibers. The animals of the treated group showed very well developed in cartilage growth in middle of the area of the operation result of chondrocytes appeared in their lacuna the isogenic groups could be seen very large in numbers at the area of operation for the same period ,there is high and very well developed in cartilage growth, there is actively synthesized matrix material this cause the total volume of cartilaginous structure to increase over well growth of the structure .There is high increase in thickness of connective tissue in same area contain mainly elastic fibers and lesser amount of collagen fibers(Fig 2).

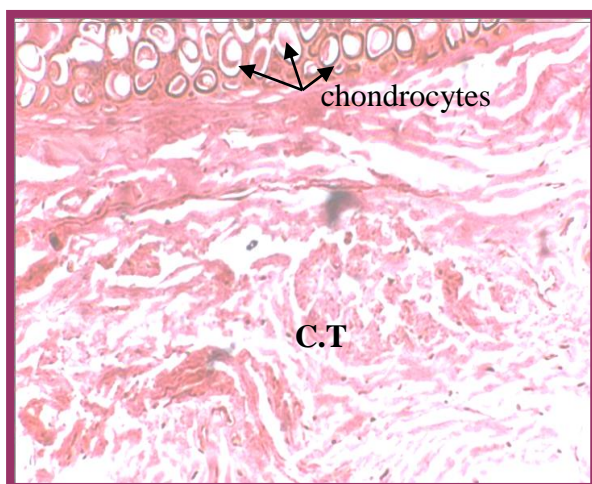


Fig 1: Specimen taken from the treated group 4 weeks post operation showed thickening of the connective tissue and presence of chondrocytes in their lacuna and chondroblasts appear at the area of operation.

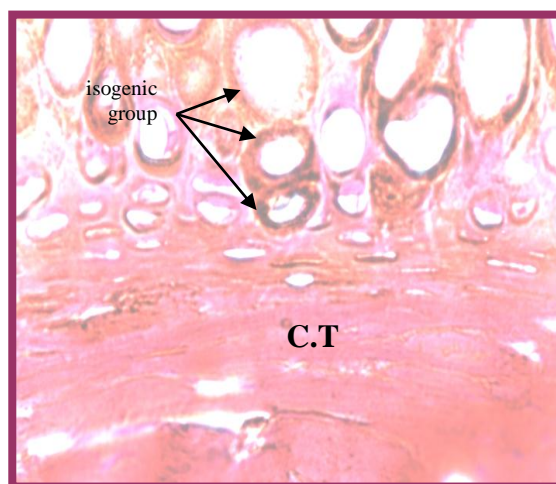


Fig 2: Specimen taken from the treated group 6 weeks post operation showed increase thickening of the connective tissue and appearances of isogenic group

Table 1: Length of axis (mm) / week for both groups ; Control and treated with He – Ne laser .

Group	Length of axis (mm) / Week			
	1 st . week	2 nd . week	4 th . Week	6 th .week
Control A	2.8 ± 0.089	2.3 ± 0.44	1.6 ± 0.34	1.1 ± 0.85
Treated B with He – Ne Laser	2.2 ± 0.58	1.6 ± 0.23	0.9 ± 0.34	Sealed
Level of Significance	*	*	*	**

*Significant

** Highly Significant

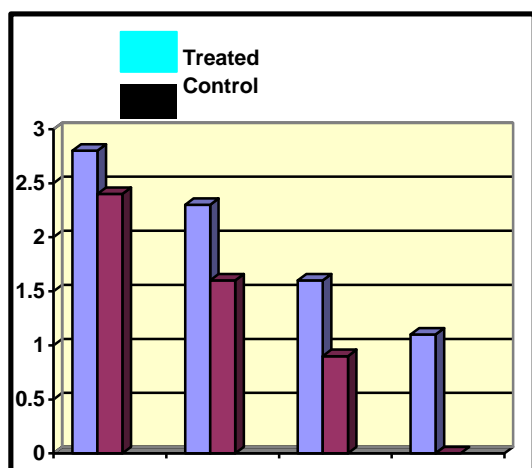


Fig: 3 Length of axis (mm) / week for both groups; control and treated with He – Ne laser.

DISCUSSION

The main purpose of this project was to determine the ability of filling a defect due to automobile accidents, avulsion due to human bites, burns and frostbites resulting in massive soft tissue loss (cartilage) with newly formed tissue which is cartilaginous in origin with just little fibrous tissue.

The clinical feasibility of this process depends upon preservation of blood supply to the cartilage which formed the boundaries of the hole left after removing the specimens. The cartilage of the ear has no other blood supply except that supplied by the overlying skin, (9). Many authors proved increasing in the vascularization of the sites irradiated with low level lasers and this has been showed to be a laser specific reaction, (10)

L.L.L.T. enhances microcirculation and seemed to be unique in normalization of the functional features of the area which irradiated with it in addition to rapid increase in the level of Adenosine, Growth hormone, GH and Fibroblast growth factor, FGF. Fiber/capillary, F/C ratio and Capillary's diameter proliferated the area with marked increase in the diameter of the original blood vessels.(11). Thus the first important factor encourage the

healing was provided by the irradiation with the He - Ne laser.

Many researches designed to evaluate different therapeutic methods which accelerate the healing of grafted cartilages without or with just little amount of fibrous tissues, one of these therapeutics are the low level lasers. A team of workers found that the laser's energy absorbed by the endogenous chromophores located in the mitochondria and cell membrane, furthermore, they proved that this energy potentiate the synthesis of RNA, DNA, proteins and various enzymes resulting in cell proliferation and earlier tissue regeneration, (5).

When the laser interacts with a biological tissues, a series of changes carried out, the therapeutic role of the laser depends on many multifactor effects on the body tissues as a whole, some of these effects take place due to transmission of the laser energy to an energy of chemical bonds in addition to non-linear optic effects like, acoustic, ultrasound, standing waves and mild ultra- violet radiation which emerge in to the body tissues, (12).

Fibroblast growth factor FGF-2 has been applied in vitro to chondrocyte cells both in monolayer culture and in three dimensional environments. It has been established that FGF-2 (also called basic fibroblast growth factor) is a potent mitogen for chondrocytes in monolayer culture and in vivo. However, reports about the use of FGF-2 to culture cartilage tissue in vitro in a three dimensional environment have been contradictory. For example, FGF-2 has been reported both to cause a waning of the mature phenotypic characteristics typical of cartilage explants and increase the rate of proliferation without affecting the mature phenotypic characteristics of chondrocyte-seeded implants in the presence of FGF-2, (13 & 14).

Prostaglandins enhance the stimulatory effect of Fibroblast Growth Factor, FGF, (15). In vitro studies have

shown increase production of prostaglandins E&F following L.L.L.T., (16). The forward facts explain how the mitotic processes stimulated in the area of incision at the early reparative stages and the increase in the number of the immature young chondrocytes which then replaced with mature chondrocytes in addition to the active interstitial cartilage growth in the treated group. . Low power laser irradiation has been reported to reduce inflammatory reactions, produce analgesia and promote regeneration and healing. Its mechanism of action is unknown, one hypothesis is that the light produces free radicals which have beneficial effects at low concentrations, (17), they accelerate the collagen and its precursor's maturation's, promote the improvement of microcirculation, , they also activate the mast cells, (18) The results of this study agreed with those obtained by Serduchenko and his colleagues, (19)

Reference:

1. Peter, L. Williams, (1999) : Skeletal system and Nervous System, chapter, 6 & 8, PP: 425 -712 & 901 – 1367, In; Gray's. Anatomy, 38th Edition.
2. Sherrell, J. A., Robert, W. B. & Charles, H. M. T., (1997): General Reconstruction, Section 1, PP: 3-99, I n; Grabb & Smith's Plastic Surgery, 5 th. Edition, Lippincott – Raven publishers.
3. Media New s Room, (2006): Cosmetic vs. Reconstructive Surgery, Surgery of the Ear , http://www.com/our_surgeons.htm .
4. Bardsley AF, Mercer DM,(1983): The injured ear: a review of 50 cases. Br J Plast Surg Oct; 1036(4): 466-9 [\[Medline\]](#) , eMedicine ; INSTANT ACCESS TO THE MINDS OF MEDICINE , (2006) : Ear, Reconstruction and Salvage
5. Chukuka, S. E., (2001) : Laser Photo stimulation, Laser Therapy13:1- 4.
6. Serduchenko, N., Vrublevski, V., Beletski, A. & Pinevitch, D., (2001) : Influence of laser radiation of blue and red region on an ultrastructure of hyaline cartilage.
7. Aleksandrov, M.T., (1992): The working scheme of mechanism biological and therapeutic effect of laser irradiation. Proceeding of the 1st Clinical and Scientific conference of the Russian State Medical University, pp.: 6- 8.
8. Nelson, J.S., Orenstein, A., Liwa, L .H. & Berus, M .W., (1989): Mid infrared erbium-yag laser ablation of bone healing, Laser, Surgery, Med., 9(4): 362-374.
9. Medicine.Net.com(2006):Cauliflower Ear, Ohshiro, T. & Calder head, <http://www.medicinenet.com/script/main/hp.asp> , 27 Feb.2006 R.G.; Low Level Laser Therapy Photobioactivation, chapter, (3), pp: 32-62,1988, John Wiley & sons Ltd.
10. Ihsan,F.R.Mohammed ,(2005) : Low Level Laser Therapy (L.L.L.T.) accelerates Collateral Circulation and enhances Microcirculation. . Photo medicine & Laser Surgery. 23 (3).
11. Golovin, S., (1992): Mechanism of laser action. Proceeding of the 1st Clinical and Scientific conference of the Russian State Medical University, pp.: 6-8, November.
12. Wroblewski.,1995: Use of growth factors and hormones for expansion of mammalian cells and tissue engineering. J. Bone Miner. Res., May, 10 (5) : 735-742. <http://www.wipo.int/ipdl> .
13. Toolanl., 1996: Use of growth factors and hormones for expansion of mammalian cells and tissue engineering. J. Biomed Mater Res., June 31 (2): 273- 280. <http://www.wipo.int/ipdl> .

14. Ganong, W.F., (1997): Synaptic and Junctional transmission. In; Review of Medical Physiology. Eighteenth edition. Chapter (4), pp: 79-110, Lange medical book.
15. Glen Calderhead, (1988): Low Level Laser Therapy, chapter (1) pp: 3-18 & chapter (3) pp: 32-62. Edited in: Low Level Laser Therapy: A Practical Introduction, T. Ohshiro & R. G. Calderhead, John Wiley & Sons.
16. Iwase – T; Hori – N; Morioka – T and Carpenter, Do., (1996). Low power laser irradiation reduces ischemic damage in hippocampal. Laser – Surg. – Med.; 19 (4):465-70.
17. Serduchenko, N., and Vrublevski, V., Beletski, A. & Pinevitch, D., (2001): Influence of laser radiation of blue and red region on an ultrastructure of hyaline cartilage.
18. Al-Sayed – SO. & Dyson, M., (1996). Effect of laser pulse repetition rate and pulse duration on mast cell number and de-granulation. Laser – Surg – medical, 19 (4): 433-7.

تأثير التشعيع بليزر الهليوم-النيون في عمليات الاصلاح النسيجي بعد فقدان الغضروفي في الارانب النيوزلندية

ابتسام خلف عبد علي*

*كلية التمريض/ جامعة بغداد

الخلاصة

استخدمت العديد من الطرق العلاجية لغرض تشجيع عمليات الالتئام في الغضروف وتسريع إعادة النمو مثل الادوية والطاقة المغناطيسية والليزر وغيرها. استخدمت في هذه الدراسة اربعة وعشرون ارنبا نيوزلندية بالغاً تم تقسيمها الى مجموعتين متساويتين (السيطرة والمعالجة بليزر الهليوم-نيون). تم استحداث قطع سدلة لسانية مربعة في الجلد على الجانب الانسي لكلا الاذنين وصولاً الى الغضروف حيث تم استحداث سدلة مربعة في كل جانب وتم سلخه عن الاذن تبعه خياطة اللسان الجلدي. تم تشجيع موقع العملية في حيوانات المعالجة بوساطة ليزر الهليوم-نيون قوته (5ملي واط) لمدة سبعة ايام بدأت بعد العملية مباشرة, تم تخصيص (3 ارانب) من كل مجموعة لغرض جمع النماذج الخاصة بالفحوصات النسيجية المرضية للاسابيع (1,2,4,6) بعد اجراء العملية. أظهرت النتائج تطور في النمو الغضروفي وبشكل ملحوظ احصائي نتيجة لغزو الخلايا الغضروفية في منطقة العملية, زيادة في سمك النسيج الضام في نفس المنطقة وغالبية من الالياف الغراوية ونسبة اقل من الالياف المرنة. رفع ليزر الهليوم-نيون القابلية الانقسامية للخلايا الغضروفية والعمليات التكاثرية علاوة على عمليات إعادة النمو الاصلاحية داخل وخارج الخلايا.