

Efficacy of vitamin D supplementation on hepcidin/ferroportin axis and VDR expression in HFHF-fed rats

Hager Mosaad Saad Abd-Elgwaad  , Heba Adel Abd El-Hamid Barakat  , Eman Hassan Abdel Aziz Sharaf  , Nourhan Gamal El-Rahmany*  

Biochemistry and Nutrition Department, Women's Faculty for Arts, Science and Education, Ain Shams University, Cairo, Egypt.

*Corresponding Author.

Received 26/09/2023, Revised 21/04/2024, Accepted 23/04/2024, Published Online First 20/06/2024,
Published 22/12/2024



© 2022 The Author(s). Published by College of Science for Women, University of Baghdad.

This is an open-access article distributed under the terms of the [Creative Commons Attribution 4.0 International License](https://creativecommons.org/licenses/by/4.0/), which permits unrestricted use, distribution, and reproduction in any medium, provided the original work is properly cited.

Abstract

Targeting the hepcidin-ferroportin axis is the key mechanism involved in metabolic health. This study aims to investigate the intertwined relationship between vitamin D status and iron homeostasis in metabolic syndrome induced by a high-fat high-fructose (HFHF) diet in rats. The experimental groups were as follows: G1; negative control, G2; positive control, G3 and G4 (balanced diet and supplemented with Vit.D₃ (12 and 24 µg/Kg b.wt respectively twice/week). G5 and G6 (HFHF diet and supplemented with Vit.D₃ (12 and 24 µg/Kg b.wt respectively twice/week). Various biochemical, molecular, and histological parameters were evaluated in serum and liver tissue homogenate. The results showed that Vit.D₃ administration significantly modulated the disrupted iron homeostasis induced by the HFHF diet through downregulation of hepatic hepcidin and upregulation of ferroportin-1 protein expression which leads to significant improvement in serum iron profile. Vit.D₃ administration also, enhanced antioxidant status by reducing elevated serum levels of malondialdehyde and increasing hemeoxygenase-1 activity. In addition to, upregulating nuclear factor erythroid 2-related factor 2 gene expression. Also, it attenuated elevated serum inflammatory biomarkers and resistin level while, significantly elevated serum adiponectin level. Furthermore, vitamin D receptor expression was upregulated in liver tissue and serum Vit. D₃ was significantly increased which ameliorated insulin resistance and disrupted lipid profile. Microscopic findings show hepatic damage, fatty infiltration while Vit.D₃ administration preserved the liver tissue.

Keywords: Hepcidin/ferroportin axis, Iron homeostasis, Metabolic syndrome, Vitamin D₃, Vitamin D₃ receptor.

Introduction

Iron is an important mineral that has roles in DNA synthesis, cellular proliferation, and cellular respiration¹. Electrons transfer and oxygen delivery in oxidation-reduction reactions are facilitated by iron, which is essential in maintaining normal cell metabolism, also through the Fenton reaction, iron results in the generation of toxic reactive oxygen species (ROS)². The induction of oxidative stress by

iron in metabolic tissues is proposed to contribute to the development of metabolic abnormalities. Thus, controlling the balance between iron uptake, storage, and utilization is required to maintain iron homeostasis and ensure optimum functioning of metabolic processes³.

The peptide hormone hepcidin is the main regulator of iron homeostasis, hepcidin controls the absorption

and transport of iron via ferroportin, (FPN-1) which is an iron exporter that regulates intestinal absorption, cellular uptake, and storage of iron in tissues. Furthermore, hepatocytes secrete hepcidin, and its synthesis is regulated by two major mechanisms: iron status and inflammatory stimuli⁴.

In addition to hepcidin, Nrf2 is another regulator of iron homeostasis, Nrf2 is a transcription factor that regulates the cellular defense against toxic and oxidative insults through the expression of genes involved in oxidative stress response and drug detoxification⁵. The increase in Nrf2 synthesis activates antioxidant defense signals. The regulation of intracellular iron levels, oxidative stress, and genes involved in iron homeostasis (ferritin heavy chain, ferritin light chain, transferrin, FPN-1, and HO-1) regulated by Nrf2, additionally, the Nrf2-mediated mechanism regulates hepcidin synthesis^{6,7}.

Excessive adiposity is associated with disturbances in iron homeostasis and development of metabolic syndrome with insulin resistance, elevation of serum glucose and triacylglycerol (TAGs). Adiposity stimulates the expression of the iron-regulatory hormone hepcidin, which can result in the deregulation of iron homeostasis^{8,9}. Adiposity leads to the release of inflammatory mediators, such as IL-6 and tumor necrosis factor alpha (TNF α), which in turn stimulate CRP release. However, adiponectin secretion is reduced, and all these processes result in a proinflammatory environment¹⁰. Adiposity is

Materials

Experimental animals:

Sixty adult male Sprague–Dawley rats (8 weeks of age and weighing 120 ± 5 g) were used in this study, and the rats were obtained from the National Research Center, Doki, Egypt. The animals were acclimated for 1 week before the experiment. The rats were maintained under 12-h light/dark cycles, the temperature was maintained at 25 °C, and the humidity was between 60% and 70%. Additionally, rats were provided with water *ad libitum*. Moreover, all animal experiments were performed under a protocol approved by the local animal ethics committee of Ain Shams University (ASU-SCI/BIOC/2022/11/2).

Experimental design

In the present study, sixty male albino rats were divided into 6 groups of 10 rats each. All international and local rules and regulations for

characterized by increased adhesion molecule levels along with increased cytokine production, leading to the stimulation of tissue-specific macrophage recruitment¹¹.

The importance of vitamin D beyond its effects on calcium homeostasis has become more evident, and its functions in cell differentiation and proliferation, immune modulation, and the inflammatory response¹². Moreover, it is known that vitamin D regulates biological functions in many tissues and organs through their receptors (VDRs), which are widespread in the body¹³. Clinical evidence indicates that an association between vitamin D deficiency and the prevalence of chronic morbid conditions exists. Additionally, vitamin D is a potent regulator of the hepcidin-ferroportin axis through the regulation of hepcidin expression¹⁴.

Vitamin D participates in cellular processes responsible for the homeostasis of glucose and lipid metabolism via the insulin signaling pathway. Moreover, disturbances in insulin signaling and inflammation are closely related, and vitamin D is reported to modulate both disorders. Vitamin D is reported to affect hepatic lipogenesis, gluconeogenesis, and ROS homeostasis^{15,16}.

This study aims to investigate the relationship between iron homeostasis and vitamin D status on metabolic dilemmas including insulin resistance, steatohepatitis, inflammation, and lipogenesis induced by HF-HF diet in rats.

handling animals throughout the experimental period (eight weeks) were followed. The experimental groups were divided as follows and shown in figure 1:

- **Group 1:** Negative control group; rats fed a balanced diet and orally administered distilled water twice per week.
- **Group 2:** Positive control group, rats fed HFHF diet and orally administered distilled water twice per week.
- **Group 3:** Rats fed a balanced diet and orally administered $1,25(\text{OH})_2\text{D}_3$ (12 $\mu\text{g}/\text{kg}$ body weight, twice per week)¹⁷.
- **Group 4:** Rats fed a balanced diet and orally administered $1,25(\text{OH})_2\text{D}_3$ (24 $\mu\text{g}/\text{kg}$ body weight, twice per week).

- **Group 5:** Rats fed HFHF diet and orally administered 1,25(OH)₂ D₃ (12 µg/kg body weight, twice per week)¹⁷.
- **Group 6:** Rats fed HFHF diet and orally administered 1,25(OH)₂ D₃ (24 µg/kg body weight, twice per week)

All rats consumed a prepared diet (balanced or HFHF) and were administered Vit.D₃ as described in the experimental design from week one of the experiment to week eight.

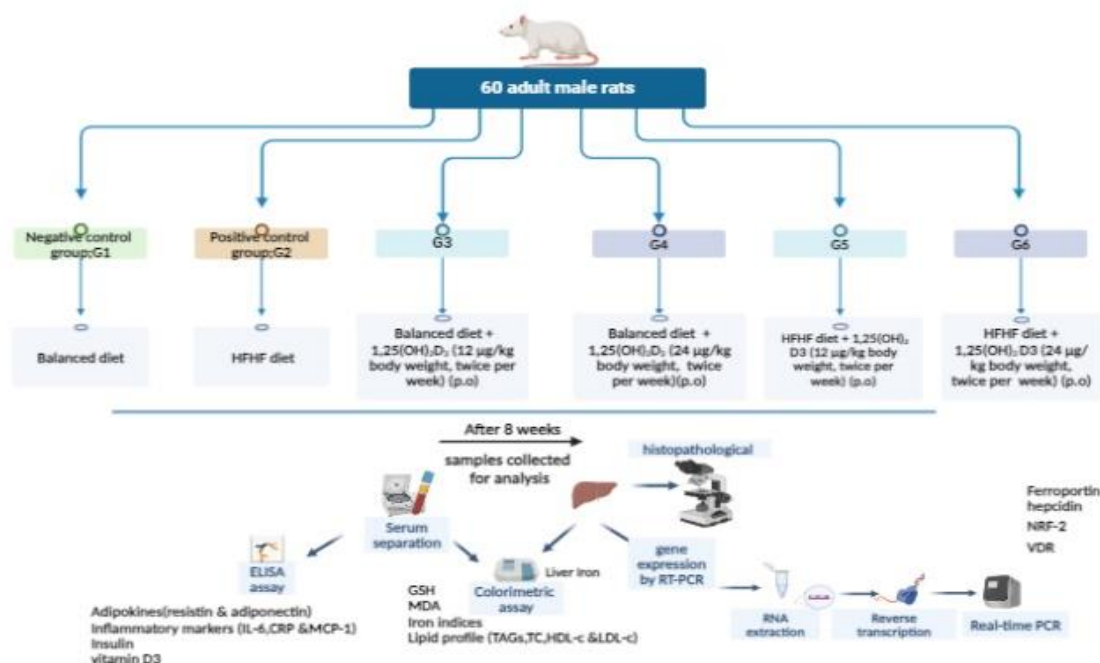


Figure 1. Graphical abstract and experimental design.

Sample collection:

At the end of the experimental period (8 weeks), rats were fasted for 12 hours and anesthetized under sodium pentobarbital at 200 mg/kg b.wt and injected intraperitoneally. Blood samples were collected from the hepatic portal vein, left for 15 minutes at room temperature, and then centrifuged at 4000 rpm for 20 minutes for serum separation. To inhibit glycolysis, samples were collected into tubes containing sodium fluoride. Then, part of the serum was immediately used for colorimetric determination of glucose levels. The remaining serum samples were kept at -20 °C for further biochemical analysis. Furthermore, liver samples were removed and washed with ice-cold saline solution and then weighed. The samples were stored at -80 °C for genetic and biochemical analysis, while liver samples used for microscopic examination were preserved in 10% formalin solution.

Chemicals:

Vitamin D₃ or 1, 25-dihydroxyvitamin D₃ (1,25 (OH)₂D₃) (2800 IU/1 ml) was purchased from Minapharm, a pharmaceutical company in Egypt.

Diet:

The experimental diets used in this study were as follows: a **standard balanced diet** was prepared according to AIN-93(M) for maintenance¹⁸. A **high-fat/high-fructose diet (HFHF)**, which consisted of 45% fat and 30% fructose¹⁹. The standard balanced diet and HFHF diet were prepared in the lab according to AIN-93(M) with a modification of fat and sugar in the case of the HFHF diet. Fine ingredients of corn starch, casein, sucrose, cellulose, L-cystine, choline chloride, Tetra-butyl hydroquinone, fructose, and the minerals used for the preparation of the mineral mixture were purchased from EL Gomhoria Company. Corn oil and fat were purchased from Arma Company and Eveco Egypt Company respectively. While for vitamin mixture preparation, nicotinic acid, calcium pantothenate, pyridoxine-hydrochloride, thiamin-hydrochloride, riboflavin, and folic acid were purchased from EL Gomhoria Company, while, biotin as Biotin forte, vitamin B-12 as Deltavit B12, vitamin E, vitamin A as A-VITON, vitamin D₃ as V-drop, and vitamin K were purchased from Unipharma, Delta, Pharco,

Kahira, Minapharm, and Pharonia PH pharmaceutical companies, Egypt respectively.

Composition of experimental diets; balanced diet and high-fat high fructose diet (HFHF) g/kg diet:

Ingredient	Balanced diet g/Kg	HFHF g/Kg
Corn starch	620.692	10.700
Casein (85% protein)	140.000	140.000
Sucrose	100.000	0.00
Corn oil	40.000	0.00
Fiber (cellulose)	50.000	50.000
Minerals mixture	35.000	35.000
Vitamins mixture	10.000	10.000
L.cystine	1.800	1.800
Choline chloride	2.500	2.500
Tetra-butylhydroxyquinone	0.008	0.008
Fructose	0.00	300
Fat	0.00	450

Composition of vitamins mixture (AIN-93 M):

Vitamin	g/Kg mix
Nicotinic acid	3.00
Calcium pantothenate	1.60
Pyridoxine-hydrochloride	0.70
Thiamin-hydrochloride	0.60
Riboflavin	0.60
Folic acid	0.20
D-Biotin	0.02
VitaminB-12 (cyanocobalamin)	2.50
Vitamin E	15.0

Vitamin A (all-trans-retinyl palmitate)	0.80
Vitamin D3 (cholecalciferol)	0.25
Vitamin K (phylloquinone)	0.075
Powdered sucrose	974.65

Composition of minerals mixture (AIN-93 M):

Mineral	g/Kg mix
Calcium carbonate, anhydrous	357.00
Potassium phosphate, monobasic	250.00
Sodium chloride	74.00
Potassium sulfate	46.60
Potassium citrate, tri-potassium, monohydrate	28.00
Magnesium oxide	24.00
Ferric citrate	6.06
Zinc carbonate	1.65
Manganous carbonate	0.63
Cupric carbonate	0.30
Potassium iodate	0.01
Sodium selenate, anhydrous	0.0102
Ammonium paramolybdate, hydrate	4 0.00795
Sodium meta-silicate, 9 hydrate	1.45
Chromium potassium sulfate, hydrate	12 0.275
Boric acid	0.0815
Sodium fluoride	0.0635
Nickel carbonate	0.0318
Lithium chloride	0.0174
Ammonium vanadate	0.0066
Powdered sucrose	209.80

Methods

Biochemical analysis:

Serum analysis

Assessment of serum iron profile

Serum iron levels and TIBC were determined by a colorimetric method²⁰ using a SPECTRUM kit (269 002& 273 001-D), respectively, Germany. Serum transferrin was measured by the quantitative sandwich enzyme-linked immunosorbent assay (ELISA) technique²¹ using KRISHGEN BioSystems kit (KBH1621), India.

Assessment of serum Vit. D₃ level

Serum vitamin D₃ level was measured according to the quantitative sandwich ELISA method²² using a MyBioSource kit (MBS728692), USA.

Assessment of serum adipokine levels

Serum adiponectin and resistin levels were determined by the quantitative sandwich ELISA technique method²³ using a MyBioSource kit (MBS068220& MBS013451) respectively (USA).

Assessment of serum inflammatory markers

Serum IL-6, CRP, and MCP-1 levels were determined by the quantitative sandwich ELISA technique^{22,23}, using Biovision kits (R6000B), USA, for IL-6, Mybiosource kits (MBS2508830), USA, for CRP and Cusabio kits (R6000B), USA, for MCP-1.

Assessment of serum oxidative biomarkers

The serum MDA concentration was determined by a colorimetric method²⁴ using a Biodiagnostic kit, Egypt. Serum HO-1 level was measured according to

the quantitative sandwich ELISA technique²³ using an Elabscience kit (MBS764989) (USA).

Assessment of serum lipid profile

TAGs and TC were determined according to the enzymatic colorimetric method^{25,26}, respectively, using the Salucea kit, Netherlands. LDL-C and VLDL-C were calculated²⁷. Furthermore, the HDL-C concentration was determined according to the enzymatic colorimetric method²⁸ using a SPECTRUM kit (266 001), Germany.

Assessment of serum glucose, insulin, and HOMA-IR

Serum glucose level was measured by the enzymatic colorimetric method²⁹ using a Diamond kit (Hannover, Germany). Moreover, serum insulin was measured by the quantitative sandwich ELISA technique³⁰ using a MyBioSource kit (MBS824729), USA. The HOMA-IR index was then calculated.³¹

Tissue analysis

Preparation of liver tissue homogenate

Liver tissue was perfused with phosphate-buffered saline at pH 7.4 containing 0.16 mg/ml heparin to remove any red blood cells and clots. Liver samples were homogenized in 5 ml cold buffer (50 mM potassium phosphate, pH 7.4, 1 mM EDTA, and 1 ml/L Triton X-100) per gram tissue and then centrifuged at 4000 rpm for 15 min at 4 °C. Finally, the supernatant removed for assay and stored on ice.

The homogenates are used to detect gene expression and liver iron concentration.

Assessment of liver iron concentration

The liver iron concentration was measured by the ferrozine chromogenic method (colorimetric assay)³² using a Metallogenics kit (FE31ME), Japan.

Quantitative gene expression of hepcidin, FPN1, Nrf2, and VDR by real-time polymerase chain reaction (RT-qPCR)

Hepcidin, FPN1, Nrf2, and VDR were detected in liver tissue samples using a Qiagen tissue extraction kit (Qiagen, USA) and a high-capacity cDNA reverse transcription kit (Fermentas, USA). qPCR conducted a fluorescence reaction of molecules that increase proportionally with the increase in DNA amplification in a thermocycler. Moreover, the double-strand DNA binding dyes (SYBR Green) function as fluorescent chemistries. A specialized thermocycler with fluorescence detection modules is the key equipment for qPCR, which is used to monitor and record the fluorescence in real time as amplification occurs. Furthermore, the qPCR measurement involves RNA isolation, reverse transcription, qPCR assay development, qPCR experiment, and data analysis. The results were statistically analyzed using the $2^{-\Delta\Delta C_t}$ method, with beta-actin as an internal reference (housekeeping gene).

Table 1. Primer sequences.

Gene	Primer's sequence	
Hepcidin	Forward sequence	5'- CACAGCAGAACAGAAGGCATG -3'
	Reverse sequence	5'- CTTCTGCTGTAAATGCTGT -3'
FPN1	Forward sequence	5'- TTGCAGGAGTCATTGCTGCTA -3'
	Reverse sequence	5'- TGGAGTTCTGCACACCATTGAT -3'
Nrf2	Forward sequence	5'- CCATGCCTTCTTCCACGAA -3'
	Reverse sequence	5'- AGGGCCCATGGATTTTCAGTT -3'
VDR	Forward sequence	5'- GATGCAGGGCTGTTTATGGG -3'
	Reverse sequence	5'- GGCCTGCTTGCTGTTCTTAC -3'
Beta-actin	Forward sequence	5'- TGT CAC CAA CTG GGA CGA TA-3'
	Reverse sequence	5'- AAC ACA GCC TGG ATG GCT AC-3'

* Ferroportin, (FPN-1), nuclear factor erythroid 2-related factor 2 (Nrf2), vitamin D receptor (VDR)

Histopathological analysis of liver tissue

The liver was dissected and fixed in 10% formalin, and paraffin-embedded tissues were stained with hematoxylin and eosin (H&E) and examined under a light microscope (Nikon lab binocular with camera) at 400 X magnification³³.

Statistical analysis

The statistical analysis of the results was performed using Statistical Package for Social Science (SPSS) software 16, USA. Data presented as the means \pm SDs and analyzed statistically by one-way analysis of variance (ANOVA). The mean differences were significant when $p < 0.05$ ³⁴.

Results

The results of the present study showed that the HFHF diet increased adiposity, leading to a decrease in adiponectin (anti-inflammatory cytokine) secretion and an increase in the secretion of resistin from adipose tissue as a response to the excessive accumulation of fat. This leads to the initiation of an inflammatory environment, especially in visceral fat. The HFHF diet induced the release of inflammatory mediators, such as IL-6, which in turn stimulated CRP and MCP-1 release due to excessive adiposity. The release of adipokines influenced by iron homeostasis, and iron homeostasis dysregulation decreases the expression of adiponectin. Decreased adiponectin is associated with glucose homeostasis disturbance and lipid profile aberrations.

Effect of vitamin D administration on serum adiponectin, resistin, IL-6, CRP, and MCP1:

From the current results in Table 2, the HFHF diet-induced alterations in serum adipokines caused a significant decrease in adiponectin and a significant increase in resistin. Additionally, there was a significant elevation in serum IL-6, CRP, and MCP-1 in the HFHF diet groups compared with the healthy control group. While Vit.D₃ administration with HFHF diet significantly decreased this elevation compared to the positive control group.

Effect of vitamin D administration on Nrf2 gene expression, serum MDA, and HO-1:

The data presented in Table 2 showed a significant increase in MDA, a significant decrease in HO-1 activity, and a significant down-regulation in Nrf2 expression compared to the negative control group. While the results of these parameters were reversed after the administration of Vit.D₃.

Table 2. Effect of vitamin D administration on adiponectin, resistin, IL-6, CRP, MCP1, Nrf2, MDA, and HO-1 in the experimental groups.

Groups	Parameters							
	Serum adiponectin (ng/ml)	Serum resistin (ng/ml)	Serum IL-6 (pg/ml)	Serum CRP (ng/ml)	Serum MCP1 (pg/ml)	Nrf2 expression in liver tissue	Serum MDA (nmol/l)	Serum HO-1 (ng/ml)
Group1	31.38± 1.36 ^a	3.08± 0.27 ^a	122.17± 1.62 ^a	17.46± 1.54 ^a	214.21± 1.18 ^a	1.00± 0.00 ^a	8.65± 0.54 ^a	8.92± 0.99 ^a
Group 2	9.21± 0.73 ^b	15.31± 1.51 ^b	253.9± 1.79 ^b	86.60± 1.60 ^b	429.26± 1.83 ^b	0.16± 0.01 ^b	19.36± 0.69 ^b	1.87± 0.23 ^b
Group 3	31.76± 1.43 ^a	2.78± 0.32 ^a	117.48± 1.76 ^c	13.58± 0.61 ^c	212.13± 1.82 ^c	2.10± 0.11 ^c	8.46± 0.40 ^a	9.14± 1.00 ^a
Group 4	32.49± 1.91 ^a	2.41± 0.19 ^a	111.62± 1.77 ^d	12.45± 0.83 ^c	211.01± 1.20 ^c	2.62± 0.12 ^d	8.25± 0.47 ^a	9.41± 0.74 ^a
Group 5	17.93± 1.55 ^c	7.40± 1.07 ^c	175.17± 1.46 ^e	33.18± 1.61 ^d	283.61± 1.94 ^d	0.56± 0.01 ^e	16.74± 0.38 ^c	4.79± 0.65 ^c
Group 6	22.89± 1.90 ^d	4.83± 0.57 ^d	151.15± 1.65 ^f	29.93± 1.60 ^e	250.38± 0.94 ^e	0.70± 0.01 ^f	15.51± 0.66 ^d	7.67± 0.55 ^d

* Interleukin 6 (IL-6), C-reactive protein (CRP), monocyte chemoattractant protein-1 (MCP-1), nuclear factor erythroid 2-related factor 2 (Nrf2), malondialdehyde (MDA), hemeoxygenase-1 (HO-1).

*All values expressed as the mean ±SD, n=10. There is no significant difference between the means that have the same alphabetical superscripts in the same column, while different letters are significantly different at P < 0.05.

Effect of vitamin D administration on hepcidin and ferroportin gene expression, serum iron, TIBC, transferrin, and liver iron levels:

Table 3 demonstrates that the HFHF diet caused significant overexpression of the hepcidin gene and down-regulation of FPN1 compared to the healthy control group. While, in comparison to the positive control group, the expression of hepcidin was significantly down-regulated, and ferroportin expression was significantly up-regulated in the

groups that were orally administered Vit. D₃. Furthermore, the results showed a significant decrease in serum iron with a significant increase in liver iron, serum TIBC, and transferrin in the HFHF diet groups. While Vit. D₃ administration reversed the effect of the HFHF diet on iron indices.

Effect of vitamin D administration on VDR gene expression in liver tissue and serum Vit. D₃ level:

The data presented in Table.3 showed a significant decrease in serum Vit. D₃ level as well as significant down-regulation of VDR expression in the positive control group compared with the healthy control

group. Whereas Vit. D₃ administration significantly restored the serum, Vit. D₃ level and significantly increased VDR expression compared to the rats fed the HF-HF diet.

Table 3. Effect of vitamin D administration on hepcidin, ferroportin, serum iron, TIBC, transferrin, liver iron, VDR, and serum Vit. D₃ in the experimental groups.

Groups	Parameters							
	Hepcidin expression in liver tissue	Ferroportin expression in liver tissue	Serum iron (µg/dL)	Total iron binding capacity (µg/dl)	Transferrin (mg/dl)	Liver iron (µmol/mg tissue)	Vitamin D receptor expression in liver tissue	Serum vitamin D ₃ (ng/ml)
Group1	1.02± 0.00 ^a	5.95± 0.52 ^a	161.17± 0.99 ^a	283.2± 1.31 ^a	222.1± 0.99 ^a	2.22± 0.15 ^a	1.01± 0.00 ^a	41.49± 1.34 ^a
Group 2	5.57± 0.51 ^b	1.02± 0.00 ^b	104.20± 1.39 ^b	347.15± 0.88 ^b	281.9± 1.59 ^b	11.87± 0.12 ^b	0.22± 0.01 ^b	12.26± 1.78 ^b
Group 3	1.02± 0.01 ^a	6.04± 0.30 ^a	161.43± 0.97 ^a	276.0± 1.56 ^c	213.0± 1.63 ^c	2.14± 0.10 ^a	1.29± 0.12 ^c	42.78± 1.12 ^a
Group 4	1.03± 0.01 ^a	6.11± 0.37 ^a	165.95± 1.15 ^c	269.1± 1.66 ^d	209.9± 1.91 ^d	2.02± 0.27 ^a	1.78± 0.09 ^d	48.37± 1.45 ^c
Group 5	2.21± 0.08 ^c	1.92± 0.18 ^c	125.51± 1.15 ^d	327.5± 1.58 ^e	237.2± 1.47 ^e	5.35± 0.22 ^c	0.66± 0.07 ^e	31.48± 1.74 ^d
Group 6	1.92± 0.18 ^d	2.22± 0.09 ^d	133.48± 1.24 ^e	312.4± 1.42 ^f	224.1± 0.87 ^f	4.43± 0.45 ^d	0.82± 0.00 ^f	34.8± 1.05 ^e

*All values expressed as the mean ±SD, n=10. There is no significant difference between the means that have the same alphabetical superscripts in the same column, while different letters are significantly different at P < 0.05.

Effect of vitamin D administration on serum TAGs, TC, VLDL-C, HDL-C, and LDL-C

The results presented in Table 4 revealed that TAG, TC, LDL-C, and VLDL-C serum levels significantly increased with a significant reduction in HDL-C serum levels in the positive control group compared to the negative control group. Whereas Vit. D₃ administration significantly decreased the elevated TAG, TC, LDL-C, and VLDL-C levels and significantly increased HDL-C levels in HFHF-fed rats compared to the positive control group. On the other hand, there was a significant decrease in serum TAG, TC, LDL-C, and VLDL-C, levels in rats fed a HFHF diet and administered Vit. D₃ compared with the positive control group.

Effect of vitamin D administration on serum glucose, insulin, and HOMA-IR

The data presented in Table 4 showed that there was a significant increase in serum glucose, insulin levels, and HOMA-IR in the positive control group compared to the negative control group. In contrast, there was a significant decrease in serum glucose, insulin, and HOMA-IR levels in rats fed the HF-HF diet and administered Vit. D₃ in a dose-dependent manner compared with the positive control group. A high dose of Vit. D₃ showed significant amelioration compared with the low dose of Vit. D₃ However, rats were fed a balanced diet and administered Vit. D₃ showed a similar observation to the healthy control group in most parameters.

Table 4. Effect of vitamin D administration on serum TAGs, TC, VLDL-C, HDL-C, LDL-C, glucose, insulin, and HOMA-IR in the experimental groups.

Groups	Parameters							
	Serum TAGs (mg/dl)	Serum TC (mg/dl)	Serum VLDL-C (mg/dl)	Serum HDL-C (mg/dl)	Serum LDL-C (mg/dl)	Serum Glucose (mmol/L)	Serum Insulin (mIU/L)	HOMA-IR
Group 1	138.53±1.83 ^a	160.92±1.81 ^a	27.71±0.36 ^a	32.1±0.73 ^a	101.11±1.91 ^a	5.14±0.13 ^a	18.00±1.49 ^a	4.10±0.32 ^a
Group 2	223.7±1.49 ^b	219.71±1.48 ^b	44.74±0.29 ^b	25.8±0.78 ^b	149.18±1.87 ^b	8.09±0.11 ^b	55.6±1.26 ^b	19.98±0.60 ^b
Group 3	128.4±1.4 ^c	148.36±1.19 ^c	25.68±0.28 ^c	36.4±1.34 ^c	86.28±1.47 ^c	4.56±0.06 ^c	21.9±1.79 ^c	4.44±0.35 ^a
Group 4	119.96±1.69 ^d	143.49±1.68 ^d	23.99±0.33 ^d	37.2±1.03 ^c	82.29±1.71 ^d	4.37±0.13 ^d	27.4±1.89 ^d	5.31±0.34 ^c
Group 5	171.92±1.83 ^e	209.83±1.38 ^e	34.38±0.36 ^e	28.3±0.94 ^d	147.15±1.45 ^e	6.79±0.18 ^e	52.0±1.94 ^e	15.70±0.79 ^d
Group 6	155.6±1.34 ^f	206.03±1.41 ^f	31.12±0.26 ^f	29.8±0.91 ^e	145.11±1.93 ^f	6.13±0.10 ^f	48.7±1.15 ^f	13.26±0.46 ^e

*Triacylglycerol (TAGs), total cholesterol (TC), very low-density lipoprotein cholesterol (VLDL-C), high-density lipoprotein cholesterol (HDL-C), low-density lipoprotein cholesterol (LDL-C), homeostatic model of assessment for insulin resistance (HOMA-IR).

*All values expressed as the mean ±SD, n=10. There is no significant difference between the means that have the same alphabetical superscripts in the same column, while different letters are significantly different at P < 0.05.

Discussion

The results of the present study showed that the HF-HF diet caused steatohepatitis due to increased lipid accumulation in the liver, increased serum inflammatory biomarkers, and ROS production that caused damage in liver tissues, which in turn affected all liver functions, including the expression of some genes, such as the upregulation of hepcidin and downregulation of FPN1, which in turn affected iron homeostasis, causing a decrease in serum iron levels and an increase in serum TIBC, transferrin and liver iron concentrations. Additionally, dysregulated iron homeostasis caused downregulation of Nrf2 gene expression. Both Nrf2 and HO-1 are associated, as HO-1 is an Nrf2-dependent gene that exerts beneficial effects through protection against oxidative injury, so the downregulation of Nrf2 led to a decrease in HO-1 levels as an antioxidant biomarker. On the other hand, the level of MDA increased due to the increase in oxidative stress.

The HFHF diet induces chronic inflammation, which is a key component in the pathogenesis of nonalcoholic fatty liver disease (NAFLD) and insulin resistance. Increased secretion of proinflammatory cytokines by macrophages leads to metabolic abnormalities³⁵.

A study used a high-fat diet (HFD) that consists of 31.99% carbohydrate, 40.7% fat, and 11.8 % protein to investigate the effects of HFD on metabolic and inflammatory conditions. Results showed that HFD induced metabolic abnormalities and inflammation through a significant increase in IL-6 and CRP levels³⁶. Furthermore, another study reported that the HF-HF diet led to an increase in MCP-1 levels due to the incidence of NAFLD³⁷. Similarly, two studies illustrated a significant decrease in serum adiponectin and an increase in resistin levels in rat groups fed HFD^{38,39}.

Additionally, adiponectin is considered an anti-inflammatory and insulin-sensitizing hormone. In obese children, the down-regulation of adiponectin expression is associated with Vit. D₃ deficiency. Vit. D₃ treatment increases adiponectin expression, which inhibits TNF- α -induced release of MCP-1. The HFHF diet induces hyperglycemia along with an elevation in free fatty acid levels, leading to Vit. D₃ deficiency, which in turn disrupts the function of mitochondria, also causes dysregulation of calcium homeostasis, resulting in increases in ROS production and leading to oxidative damage. Vit. D₃ possesses indirect antioxidant properties and reduces the oxidative stress caused by HF-HF diet through its

antioxidant capacity. For that, Vit. D₃ could improve all the alterations in the biochemical parameters caused by HFHF diet consumption. Additionally, Vit. D₃ activates Nrf2 expression, thus increasing the antioxidant pathways⁴⁰.

The observations of the present study were similar to another study that examined the effect of HFD on the activation of Nrf2 by dividing the experimental rats into groups fed on a standard diet, HFD, and low-fat diet. The results showed a significant down-regulation of Nrf2 expression, thus decreasing the antioxidant signaling pathway³⁹. Also, the same results were confirmed by the results of a study that investigated the effect of HFD on HO-1 level in C57Bl6 male mice aged 8 weeks and fed on HFD for 8 weeks. The results of this study reported that HO-1 levels decreased in groups fed HFD⁴¹. Similarly, a study in which mice were fed on HFFD and received fructose in their drinking water (supplied ad libitum for 8 weeks), showed that the HFHF diet caused lipid peroxidation and oxidative stress that was confirmed by a significant increase in MDA level⁴².

A study reported that hepatic hepcidin expression was significantly elevated in mice fed on HFD and developed NAFLD. Moreover, the overexpression of hepatic hepcidin in mice with NAFLD was associated with hepatic iron deposition, which constitutes a physiological response of the liver to decrease circulating iron levels⁴³.

Furthermore, a study was performed on a total of 237 children, from 5 to 18 years old, 180 with primary obesity and 57 healthy children and adolescents, were enrolled. Complete blood count, serum iron levels, iron-binding capacity, ferritin levels, leptin, hepcidin, and adiponectin levels were studied. The results showed that ferritin levels were higher in a group of obese school children than in a control group, together with an opposite correlation between transferrin saturation and adiposity also a higher level of TIBC in an obese population was observed when compared with controls⁴⁴.

Furthermore, a previous study reported that increased hepatic iron levels induce liver fat deposition and insulin resistance. The development of steatosis is a characteristic feature of hepatic insulin resistance, where secreted inflammatory cytokines induce lipogenic gene expression, promote de novo lipogenesis, and impair hepatic and insulin sensitivity⁴⁵.

In the present study, the development of NAFLD due to HF-HF diet caused alterations in the serum lipid profile, and a marked elevation in TAG, TC, LDL-C, and VLDL-C levels and a reduction in HDL-C levels were observed. The excessive lipid accumulation around cells and the inflammatory condition caused by the HF-HF diet led to the development of insulin resistance (IR). The condition of IR is associated with the elevation of serum glucose, insulin, and HOMA-IR levels. On the other hand, the HFHF diet reduced the serum vit.D₃ level also down-regulated the expression of the VDR gene in liver tissue. This deficiency is due to the increase in hepatic de novo lipogenesis and the development of NAFLD. Additionally, the histopathological data are in line with the biochemical findings. Dyslipidemia observed in the groups where rats were fed the HF-HF diet was due to lipid peroxidation and the accumulation of fat in liver tissue that was responsible for NAFLD progression.

In parallel with the present results, a study that fed mice HFD established an NAFLD model. In this study, the lipid profile of the HFD group showed a significant increase in TAGs, TC, VLDL-C, and LDL-C. In contrast, HDL-C levels significantly decreased⁴⁶. Another study examined the effects of the HF-HF diet on metabolic health. The results showed that serum glucose levels increased in the HFHF diet groups and were associated with a marked elevation in the lipid profile³⁶. Furthermore, a study reported that the NAFLD condition is characterized by insulin resistance, hepatic steatosis, and inflammation⁴⁷. Additionally, another study showed that obesity leads to decrease in adiponectin and increase in resistin which associated with insulin resistance, increasing HOMA-IR and TAGs values⁴⁸.

The results of the current study agree with those previously reported by another study illustrated that low Vit. D₃ levels are associated with glucose intolerance, insulin resistance, metabolic syndrome, and increased risk for type 2 diabetes development⁴⁹. Moreover, Vit. D₃ alleviates insulin resistance by improving insulin signaling. An increase in insulin sensitivity occurs via the binding of calcitriol to VDR, which activates the peroxisome proliferator-activated receptor (PPAR), which is involved in the metabolism of fatty acids. Thus, Vit. D₃ improves glucose and lipid metabolism and enhances insulin sensitivity⁴⁰.

A study reported that when consuming the HF-HF diet, liver histopathological examination showed severe hepatic steatosis (78.33%), leading to steatohepatitis accompanied by an increase in triglyceride and total cholesterol levels. Similarly, a study investigated the effect of the HF-HF diet on liver cells⁵⁰. The results showed that the HFHF diet induced hepatocyte damage with microvascular steatosis as well as inflammation, and increased ROS generation. The histological examination of liver tissue in the present study showed similar results³⁶.

Vitamin D₃ has been reported to have direct anti-inflammatory effects, attenuating inflammation, and insulin resistance, which explains the results of the present study. Vit. D₃ significantly decreased serum resistin, IL-6, MCP-1, and CRP levels, which caused a significant increase in serum adiponectin levels, enhanced insulin sensitivity, and attenuated inflammation. Additionally, studies have reported that the anti-inflammatory effect of VDR activation is linked to the beneficial effect of VDR activators on liver glucose, lipid metabolism, and insulin resistance in HFD-fed mice. Vit. D₃ binds to VDR to induce VDR physiological function. VDR was reported to be highly expressed in nonparenchymal cells such as Kupffer cells, hepatic stellate cells, and endothelial cells; thus, activation of VDR in hepatic cells is expected to have anti-inflammatory effects, preventing the development of liver inflammation, steatosis, and IR³⁵.

A similar observation to the present study reported by a study showed that the administration of Vit. D₃ at doses of 800 IU and 2400 IU improved the inflammatory condition. The study showed that the active form of Vit. D₃, that is, 1,25 (OH)₂D₃, can increase Iκβ protein in preadipocyte cells and initiate the reduction of IL-6 and MCP-1 release⁵¹. Another study investigated the effect of Vit. D₃ supplementation in obese patients and the results illustrated that, Vit. D₃ supplementation attenuates adipose tissue inflammation by affecting adipokine as increasing adiponectin secretion⁴⁹.

Additionally, a study reported that in Vit. D₃ supplementation down-regulated the mRNA expression of the hepcidin gene. On the other hand, serum iron concentrations increased because of Vit. D₃ action⁵².

A study reported that the indirect antioxidant effect of Vit. D₃ supplementation reversed the harmful

effect of oxidative stress by diminishing ROS formation and improving the expression of Nrf2 and HO-1⁵³. While another study showed a significant elevation in HO-1 activity after supplementation with Vit. D₃⁵⁴.

Furthermore, another study investigated the effect of Western diet intake and administration of 800 and 2000 UI/kg body weight vitamin D₃ on the lipid profile. The results showed that the administration of Vit D₃ led to a reduction in TC, LDL-C, and TAG concentrations. The higher dose of the vitamin gave better results than the lower dose. Vitamin D₃ supplementation significantly attenuated HFD-induced hyperglycemia and hyperinsulinemia. Vitamin D₃ administration also significantly improved HFD-induced glucose and insulin intolerance⁵⁵. These observations are in line with the current results, Vit. D₃ administration significantly decreased serum glucose levels and HOMA-IR values.

The microscopic examination of the hepatic tissue of rats in G1 (-ve control group), G3 and G4 (fed balanced diet and administered Vit. D₃) represented by Fig. 2a, c & d showed normal hepatic tissue, while liver sections of the HFHF-treated group (G2) revealed severe hepatic damage, such as dilatation of the portal vein, vacuolar degeneration, and fatty infiltrations, as shown in Fig. 2 b. Moreover, rats were fed the HF-HF diet and administered Vit. D₃ (12 μg/kg body weight) showed remarkable preservation of the hepatic tissue Fig. 2e, whereas Fig. 2 f shows significant improvement in hepatic tissue from rats fed the HF-HF diet and administered Vit. D₃ (24 μg/kg body weight). Finally, the biochemical data obtained were in line with the microscopic observations.

The effect of Vit. D₃ supplementation (1000 IU/kg; 3 days/week) on liver tissue was illustrated in a study in which VDR expression significantly increased. The diminished expression of VDR was associated with hepatic areas, as indicated by the widening of central veins, portal tracts, and sinusoidal spaces in addition to the presence of necrotic hepatocytes. However, the hepatic expression of VDR and the liver tissue architecture were restored by Vit. D₃ supplementation⁵⁶. Also another study in which liver from HFHF diet-fed rats showed fatty changes in the hepatocyte with macro- and micro-vesicular fat droplets^{57,58}.

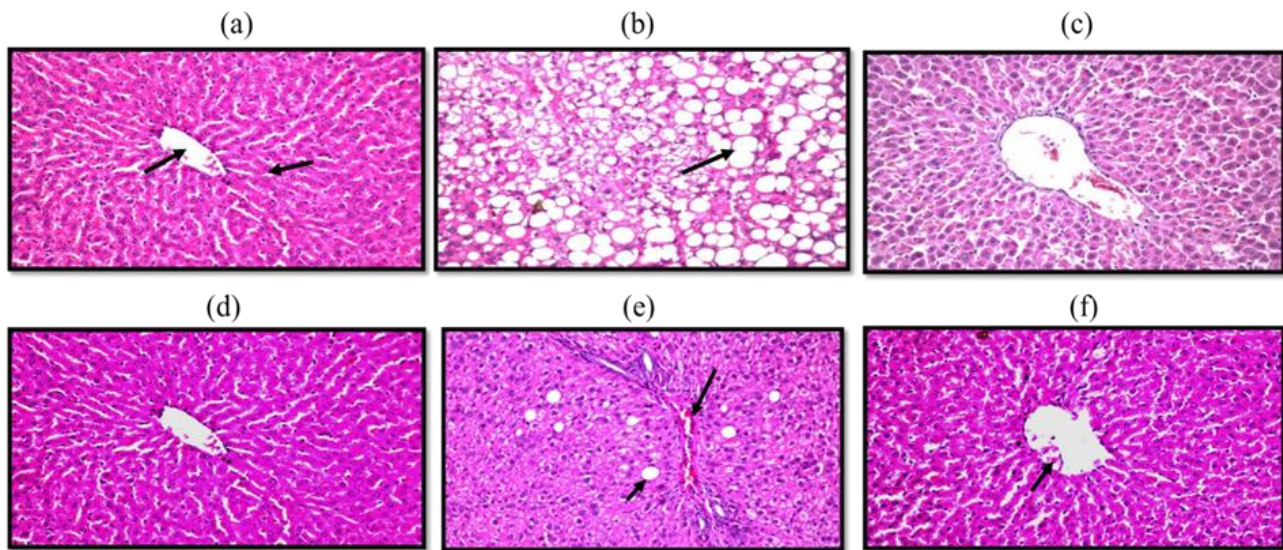


Figure 2. Microscopic examination of rat's liver tissue.

Figure 2a. Photomicrograph of hepatic tissue from the healthy control group (-ve control group): no histopathological alterations in the central vein and surrounding hepatocytes in the lobules of the parenchyma (H&E X 400). **b: Photomicrograph of hepatic tissue of rats fed the HF-HF diet (+ve control group):** fatty change detected in a diffuse manner all over the hepatocytes in the parenchyma (H&E X 400). **c: Photomicrograph of hepatic tissue from G₃ mice (fed a balanced diet and administered vit. D₃, 12 µg/kg body weight, twice per week)** showed no histopathological alteration (H&E X 400). **d: Photomicrograph of hepatic tissue of G₄ (fed a**

balanced diet and administered by vit. D₃, 24 µg/kg body weight, twice per week) showed no histopathological alteration (H&E X 400). **e: Photomicrograph of hepatic tissue of G₅ (fed HF-HF diet and administered vit. D₃, 12 µg/kg body weight, twice per week)** shows fatty changes in a few individual hepatocytes with little inflammatory cell infiltration in the portal area (H&E X 400). **f: Photomicrograph of hepatic tissue of G₆ (fed HF-HF diet and administered vit. D₃, 24 µg/kg body weight, twice per week)** in which the central vein showed mild dilatation (H&E X 400).

Conclusion

From the results of the present study, the conclusion is that, Vit. D₃ administration attenuated the iron homeostasis deregulation and the metabolic disorder caused by HFHF diet consumption, repletion of Vit. D₃ levels resulted in significant improvements in insulin sensitivity and VDR expression and attenuated inflammation and oxidative damage. The

results also showed that a high dose of Vit. D₃ administration (24 µg/kg body weight) showed more significant improvement in the parameters. Finally, this study provides therapeutic insights into the effect of vitamin D repletion on the hepcidin/ferroportin axis and VDR expression in HFHF diet-fed rats.

Acknowledgment

We would like to acknowledge Dr. Adel Beker, professor of pathology, faculty of Veterinary

Medicine, Cairo University for imaging and reporting microscopic examination results.

Authors' Declaration

- Conflicts of Interest: None.

- We hereby confirm that all the Figures and Tables in the manuscript are ours. Furthermore, any

Figures and images, that are not ours, have been included with the necessary permission for re-publication, which is attached to the manuscript.

- The author has signed an animal welfare statement.
- Ethical Clearance: The project was approved by the local ethical committee at Ain Shams University.
- Ethical Clearance: This study follows guidelines for the care and use of experimental animals

Authors' Contribution Statement

H.A.B, E.H.A, and N.G.R supervised the study and were responsible for designing the experimental operations writing, and revision the manuscript. H.M.S performed the experiments and was

established by the Committee for Control and Supervision of Experiments on Animals. Animal procedures were also made by the Faculty of Science Protocol, Ain Shams University (ASU-SCI/BIOC/2022/11/2).

- No human studies are present in the manuscript.
- No potentially identified images or data are present in the manuscript.

References

1. Marku A, Galli A, Marciani P, Dule N, Perego C, Castagna M. Iron Metabolism in Pancreatic Beta-Cell Function and Dysfunction. *Cells*. 2021; 10 (2841): 1-17. <https://doi.org/10.3390/cells10112841>
2. Qiu F, Wu L, Yang G, Zhang C, Liu X, Sun X, et al. The role of iron metabolism in chronic diseases related to obesity. *Mol Med*. 2022; 28 (130): 1-14. <https://doi.org/10.1186/s10020-022-00558-6>
3. Zhang S, Xin W, Anderson GJ, Li R, Gao L, Chen S, et al. Double-edge sword roles of iron in driving energy production versus instigating ferroptosis. *CDD press*. 2022; 13:40. <https://doi.org/10.3389/fphar.2020.00907>
4. Saneela S, Iqbal R, Raza A, Qamar M.F. Hcpicidin: A key regulator of iron. *J Pak Med Assoc*. 2019; 69(8): 1170-1175.
5. He F, Ru X, Wen T. NRF2, a Transcription Factor for Stress Response and Beyond. *Int J Mol Sci*. 2020; 21 (4777): 1-23. <https://doi.org/10.3390/ijms21134777>
6. Chorley BN, Campbell MR, Wang X, Karaca M, Sambandan D, Bangura F, et al. Identification of novel NRF2-regulated genes by ChIP-Seq: Influence on retinoid X receptor alpha. *Nucleic Acids Res*. 2012; 40: 7416-7429. <https://doi.org/10.1093/nar/gks409>
7. Hammad M, Raftari M, Cesário R, Salma R, Godoy P, Emami S.N, et al. Roles of Oxidative Stress and Nrf2 Signalling in Pathogenic and Non-Pathogenic Cells: A Possible General Mechanism of Resistance to Therapy. *Antioxidants*. 2023; 12 (1371): 1-32. <https://doi.org/10.3390/antiox12071371>
8. Heslin MA, O'Donnell A, Buffini M, Nugent PA, Walton J, Flynn A, et al. Risk of Iron Overload in Obesity and Implications in Metabolic Health. *Nutrients*. 2021; 13: 1-16. <https://doi.org/10.3390/nu13051539>
9. Hameed E, Al-Ameri L, Hasan H, Abdulqahar Z. The Cut-off Values of Triglycerides - Glucose Index for Metabolic Syndrome Associated with Type 2 Diabetes Mellitus. *Baghdad Sci J*. 2022; 19(2): 340-346. <http://dx.doi.org/10.21123/bsj.2022.19.2.0340>
10. González-Domínguez Á, Visiedo-García F, Domínguez-Riscart J, González-Domínguez R, Mateos R, Lechuga-Sancho A. Iron Metabolism in Obesity and Metabolic Syndrome. *Int J Mol Sci*. 2020; 21 (5529): 1-27. <https://doi.org/10.3390/ijms21155529>
11. Zorena K, Jachimowicz-Duda O, Si-ezak D, Robakowska M, Mrugacz M. Adipokines and Obesity. Potential Link to Metabolic Disorders and Chronic Complications. *Int J Mol Sci*. 2020; 21: 35-70. <https://doi.org/10.3390/ijms21103570>
12. Bennour I, Haroun N, Sicard F, Mounien L, Recent insights into vitamin D, adipocyte, and adipose tissue biology. *Obesity Rev*. 2022; 23: e13453. <https://doi.org/10.1111/obr.13453>
13. Carlberg C. Nutrigenomics of vitamin D. *Nutrients*. 2019; 11(3): 676. <https://doi.org/10.3390/nu11030676>
14. Lee Y, Kim G, Park S, Lim J. Vitamin D Rescues Pancreatic β Cell Dysfunction due to Iron Overload via Elevation of the Vitamin D Receptor and Maintenance of Ca²⁺ Homeostasis. *Mol Nutr Food Res*. 2021; 65 (2000772): 1-11. <https://doi.org/10.1002/mnfr.202000772>
15. Marziou A, Philouze C, Couturier C, Astier J, Obert P, Landrier J, et al. Vitamin D Supplementation Improves Adipose Tissue Inflammation and Reduces Hepatic Steatosis in Obese C57BL/6J Mice. *Nutrients*. 2020; 12 (342): 1-13. <https://doi.org/10.3390/nu12020342>
15. Szymczak-Pajor I, Drzewoski J, Sliwinska A. The Molecular Mechanisms by Which Vitamin D

- Prevents Insulin Resistance and Associated Disorders. *Int J Mol Sci.* 2020; 21 (6644): 1-34. <https://doi.org/10.3390/ijms21186644>
16. Santos RS, Vianna LM. Effect of cholecalciferol supplementation on blood glucose in an experimental model of type 2 diabetes mellitus in spontaneously hypertensive rats and Wistar rats. *Clinica Chimica Acta.* 2005; 358 (2005): 146 – 150. <https://doi.org/10.1016/j.cccn.2005.02.020>
 17. Reeves P, Nielsen F, Fahey G. AIN-93 Purified Diets for Laboratory Rodents: Final Report of the American Institute of Nutrition Ad Hoc Writing Committee on the Reformulation of the AIN-76A Rodent Diet. *J Am Nutr Assoc.* 1993; 123 (11): 1939 - 1951. <https://doi.org/10.1093/jn/123.11.1939>
 18. Genedy E, Mohamed E, Sharaf E, Shosha N, Ismail S. Ameliorative Effect of Olive Seed or Nano-olive Seed Powder Against Endothelial Dysfunction Induced by High Fat-High Fructose Diet in Rats. *Int J Food Sci Biotec.* 2020; 5(4): 84-96. <https://doi.org/10.11648/j.ijfsb.20200504.18>
 19. Fairbanks V, Klee G. Biochemical aspects of hematology. *Fundamentals of clinical chemistry.* 3rd ed. Philadelphia: W.B. Saunders Company; 1987. 789-824 p. <https://doi.org/10.1373/49.1.175>
 20. Friedman R, Young D. Effects of disease on clinical laboratory tests. 5th ed. Washington DC: AACC Press; 2001. 50-55 p. <https://doi.org/10.1093/clinchem/48.4.682a>
 21. Toi M, Harris A, Bicknell R. Interleukin 4 is a potent mitogen for capillary endothelium. *Biochem Biophys Res.* 1991; 174 (3): 1287-1293. [https://doi.org/10.1016/0006-291x\(91\)91561-p](https://doi.org/10.1016/0006-291x(91)91561-p)
 22. Hirano T. *The Cytokine Handbook.* 3rd ed. New York: Academic Press; 1998. 197-228 p. <https://doi.org/10.0126896623ISBN13:09780126896626>
 23. Ohkawa H, Ohishi N, Yagi K. Assay of lipid peroxides in animal tissues by thiobarbituric acid reaction. *J Anal Biochem.* 1979; 95: 351-358. [https://doi.org/10.1016/0003-2697\(79\)90738-3](https://doi.org/10.1016/0003-2697(79)90738-3)
 24. Fassati P, Princip L. Measurement of serum TG calorimetrically with an enzyme that produces H₂O₂. *Clin Chem.* 1982; 28: 2077-2080. <https://doi.org/10.1093/clinchem/28.10.2077>
 25. Allain C, Poon L, Chan CS, Richmond W, Fu PC. Enzymatic Determination of total serum cholesterol. *Clin Chem.* 1974; 20 (4): 470-475. <https://doi.org/10.1093/CLINCHEM/20.4.470>
 26. Friedewald W, Levy R, Fredrickson D. Estimation of the concentration of low-density lipoprotein cholesterol in plasma without use of the preparative ultracentrifuge. *Clin Chem.* 1972; 18: 499-502. <https://doi.org/10.1093/CLINCHEM/18.6.499>
 27. Lopes-Virella M, Stone P, Ellis S, Colwell J. Cholesterol determination in high-density lipoproteins separated by three different methods. *Clin chem.* 1977; 23 (5): 882-884. <https://doi.org/10.1093/clinchem/23.5.882>
 28. Trinder. Determination of glucose in blood using glucose oxidase with an alternative oxygen receptor. *Ann Clin Biochem.* 1969; 6: 24-27. <https://doi.org/10.1136/jcp.22.2.158>
 29. Young DS. Effects of drugs on clinical laboratory tests. *Ann Clin Biochem.* 1997; 34(6): 579-581. <https://doi.org/10.1177/000456329703400601>
 30. Matthwes D, Hosker J, Rudenski A, Infirmary R. Homeostatic model assessment: insulin resistance and beta cell function from fasting plasma glucose and insulin concentrations in man. *Diabetol.* 1985; 28: 412-419. <https://doi.org/10.1007/BF00280883>
 31. Yasumasa I, Iori O, Soichiro T, Mizuki I, Yuya H, Yuki I, et al. Iron Chelation by Deferoxamine Prevents Renal Interstitial Fibrosis in Mice with Unilateral Ureteral Obstruction. *PLoS One.* 2014; 9(2): 1-10. <https://doi.org/10.1371/journal.pone.0089355>
 32. Drury R, Wallington E. *Carleton's Histological Techniques.* 5th ed. New York: Oxford University Press; 1980. 126-133 p. <https://doi.org/133.8100324>
 33. Zealure CH. *SPSS Basics: Techniques for a First Course in Statistics.* 6rd ed. United States of America: 2016.
 34. Dong B, Zhou Y, Wang W, Scott J, Kim K, Sun Z, et al. Vitamin D Receptor Activation in Liver Macrophages Ameliorates Hepatic Inflammation, Steatosis, and Insulin Resistance in Mice. *Hepatology.* 2020; 71 (5): 1559- 1574. <https://doi.org/10.1007/s11306-021-01800-8>
 35. Yustisia I, Tandiar D, Cangara H, Hamid F, Daud A. A high-fat, high-fructose diet-induced hepatic steatosis, renal lesions, dyslipidemia, and hyperuricemia in nonobese rats. *Heliyon.* 2022; 8 (2022) 10896: 1-9. <https://doi.org/10.1016/j.heliyon.2022.e10896>
 36. Syarif, Rasyid H, Aman M, Lawrence G, Bukhari A, Patellongi I, et al. The Effects of High Fat Diet on the Incidence of Obesity and Monocyte Chemoattractant Protein-1 Levels on Histological Changes in Prostate Wistar Rats. *Res Rep Urol.* 2024; 16: 57–63. <https://doi.org/10.2147/RRU.S437322>
 37. Rosas-Campos R, Meza-Rios A, Rodriguez-Sanabria J, Rosa-Bibiano RDI, Corona-Cervantes K, García-Mena J, et al. Dietary supplementation with Mexican foods, *Opuntia ficus indica*, *Theobroma cacao*, and *Acheta domesticus*: Improving obesogenic and microbiota features in obese mice. *Front Nutr.* 2022; 9: 987222. <https://doi.org/10.3389/fnut.2022.987222>
 38. Aldayel S. Apigenin attenuates high-fat diet-induced nephropathy in rats by hypoglycemic and hypolipidemic effects, and concomitant activation of the Nrf2/antioxidant axis. *J Funct Foods.* 2022; 99: 1-13. <https://doi.org/10.1016/j.jff.2022.105295>
 39. Szymczak-Pajor I, Drzewoski J, Sliwiska A. The Molecular Mechanisms by Which Vitamin D

- Prevents Insulin Resistance and Associated Disorders. *Int J Mol Sci.* 2020; 21(18): 1- 34. <https://doi.org/10.3390/ijms21186644>
40. Zhang L, Li Y, Sun D, Bai F. Protective Effect of Nimbolide against High Fat Diet-induced Obesity in Rats via Nrf2/HO-1 Pathway. *J Oleo Sci.* 2022; 71(5): 709-720. <https://doi.org/10.5650/jos.ess21389>
41. Abo El-Magd N, El-Mesery M, El-Karef A, El-Shishtawy M. Amelioration effect of black seed oil against high-fat diet-induced obesity in rats through Nrf2/HO-1 pathway. *J Food Biochem.* 2021; 45: e13693. <https://doi.org/10.1111/jfbc.13693>
42. Li Y, Jiang W, Feng Y, Wu L, Jia Y, Zhao R. Betaine Alleviates High-Fat Diet-Induced Disruption of Hepatic Lipid and Iron Homeostasis in Mice. *Int J Mol Sci.* 2022; 23 (6263): 1-14. <https://doi.org/10.3390/ijms23116263>
43. Sal E, Yenicesu I, Celik N, Pasaoglu H, Celik B, Pasaoglu OT, et al. Relationship between obesity and iron deficiency anemia: Is there a role of hepcidin?. *Hematology.* 2018; 2018(23): 542–548. <https://doi.org/10.1080/10245332.2018.1423671>
44. Hilton C, Sabaratnam R, Drakesmith H, Karpe F. Iron, glucose and fat metabolism and obesity: an intertwined relationship. *Int J Obes.* 2023; 47: 554-563. <https://doi.org/10.1038/s41366-023-01299-0>
45. Li Y, Jiang W, Feng Y, Wu L, Jia Y, Zhao R. Betaine Alleviates High-Fat Diet-Induced Disruption of Hepatic Lipid and Iron Homeostasis in Mice. *Int J Mol Sci.* 2022; 23(6263): 1-14. <https://doi.org/10.3390/ijms23116263>
46. Poniachik, J, Roblero J, Urzúa A, Cattaneo M. New definition for nonalcoholic fatty liver disease. *J Hepatol.* 2021; 2021(74): 982-983. <https://doi.org/10.1016/j.jhep.2020.09.002>
47. Abed B, Farhan L, Dawood A. Relationship between serum Nesfatin-1, Adiponectin, Resistin concentration and Obesity with Type 2 Diabetes Mellitus. *Baghdad Sci J.* 2024; 21(1): 117-123. <https://doi.org/10.21123/bsj.2023.8119>
48. Szymczak-Pajor I, Miazek K, Selmi A, Balcerczyk A, Sliwińska A. The Action of Vitamin D in Adipose Tissue: Is There the Link between Vitamin D Deficiency and Adipose Tissue-Related Metabolic Disorders?. *Int J Mol Sci.* 2022; 23 (956): 1-35. <https://doi.org/10.3390/ijms23020956>
49. García-Berumen I, Ortiz-Avila O, Vargas-Vargas A, Rosario-Tamayo A, Guajardo-López C, Saavedra-Molina A, et al. The severity of rat liver injury by fructose and high fat depends on the degree of respiratory dysfunction and oxidative stress induced in mitochondria. *Lipids Health Dis.* 2019; 18(78): 1-13. <https://doi.org/10.1186/s12944-019-1024-5>
50. Sundari L, Bakta M, Astawa M, Adiatmika G, Arijana N, Tunas K. The Effect of Vitamin D Administration on Leptin, Adiponectin, and mRNA MCP-1 Levels in Adipose Tissue of Obese Female Wistar Rats. *Curr Res Nutr Food Sci Jour.* 2020; 8(2): 541-549. <https://dx.doi.org/10.12944/CRNFSJ.8.2.20>
51. Jeong Y, Jung H, Lee M, Son Y, Kim S, An W, et al. Effects of cholecalciferol and omega-3 fatty acids on hepcidin levels in 5/6 nephrectomy rats. *Kosin Med J.* 2023; 1-9. <https://doi.org/10.7180/kmj.23.137>
52. Zhang H, Liu Y, Fang X, Gu L, Luo C, Chen L, et al. Vitamin D3 Protects Mice from Diquat-Induced Oxidative Stress through the NF-κB/Nrf2/HO-1 Signaling Pathway. *Oxid Med Cell Longev.* 2021; 2021: 1-15. <https://doi.org/10.1155/2021/6776956>
53. Wang P, Yao D, Hu Y, Li Y. Vitamin D Improves Intestinal Barrier Function in Cirrhosis Rats by Upregulating Heme Oxygenase-1 Expression. *Biomol Ther.* 2019; 27(2): 222-230. <https://doi.org/10.4062/biomolther.2018.052>
54. Cordeiro M, Biscaia B, Brunoski J, Ribeiro A, Franco N, Scomparin, X. Vitamin D supplementation decreases visceral adiposity and normalizes leptinemia and circulating TNF-α levels in western diet-fed obese rats. *Life Sci.* 2021; 278 (2021): 119550. <https://doi.org/10.1016/j.lfs.2021.119550>
55. Almasmouma H, Refaata B, Ghaitha M, Almainib A, Idrisa S, Ahmada J, et al. Protective effect of Vitamin D3 against lead-induced hepatotoxicity, oxidative stress, immunosuppressive and calcium homeostasis disorders in rat. *Environ Toxicol Pharmacol.* 2019; 72(103246): 1-13. <https://doi.org/10.1016/j.etap.2019.103246>
56. Simoes I, Janikiewicz J, Bauer J, Karkucinska-Wieckowska A, Kalinowski P, Dobrzyń A, et al. Fat and Sugar—A Dangerous Duet. A Comparative Review on Metabolic Remodeling in Rodent Models of Nonalcoholic Fatty Liver Disease. *Nutrients.* 2019; 11(12): 2871. <https://doi.org/10.3390/nu11122871>
57. Solanki ND, Vadi K, Patel S. Alleviating effect of *Ficus racemosa* in high-fat-high-fructose diet-induced non-alcoholic fatty liver disease. *Indian J Physiol Pharmacol.* 2021; 65(1): 12-20. https://doi.org/10.25259/IJPP_406_2020
58. Solanki ND, Vadi K, Patel S. Alleviating effect of *Ficus racemosa* in high-fat-high-fructose diet-induced non-alcoholic fatty liver disease. *Indian J Physiol Pharmacol.* 2021; 65(1): 12-20. https://doi.org/10.25259/IJPP_406_2020

تأثير مكملات فيتامين د على محور الهيبسيدين/الفيروبورتين وتعبير مستقبلات فيتامين د في الفران المغذاه على وجبة عالية الدهون-عالية الفركتور

هاجر مسعد سعد عبد الجواد، هبة عادل عبد الحميد بركات، ايمان حسن عبد العزيز شرف، نورهان جمال الرحماني

قسم الكيمياء الحيوية والتغذية، كلية البنات للآداب والعلوم والتربية، جامعة عين شمس، القاهرة، مصر.

الخلاصة

يعد إستهداف محور الهيبسيدين- فيروبورتين هو الآلية الرئيسية المشاركة في الصحة الايضيه. تهدف هذه الدراسة إلي دراسة العلاقة المتشابهة بين حالة فيتامين د وتوازن الحديد في متلازمة التمثيل الغذائي الناجم عن إتباع نظام غذائي عالي الدهون وعالي الفركتور في الجرذان. كانت المجموعات التجريبيه علي النحو التالي G1 التحكم السلبي ، G2التحكم الموجب ، G3 وG4 (نظام غذائي متوازن ومدعم بفيتامين د 12و24 ميكروجرام / كجم من وزن الجسم علي التوالي مرتين في الاسبوع) . G5 وG6 (نظام غذائي عالي الدهون وعالي الفركتور لمدعم بفيتامين د 12و24 ميكروجرام / كجم من وزن الجسم علي التوالي مرتين في الاسبوع). تم تقييم الحديد من العوامل البيوكيميائية والجزئية والنسجيه في السيرم وأنسجة الكبد . أظهرت النتائج أن تناول فيتامين د عدل بشكل كبير توازن الحديد المضطرب الناتج عن النظام الغذائي العالي في الدهون والفركتور من خلال تنظيم محور الهيبسيدين-الفيروبورتين مما يؤدي إلي تحسن كبير في مستوي الحديد في السيرم ، كما أن تناول فيتامين د يعزز حالة مضادات الاكسده عن طريق تقليل نشاط مستوى الMDA وزيادة نشاط HO-1 في السيرم بالإضافة إلي تنظيم التعبير الجيني لNrf2 . كما أنه يخفف من ارتفاع المؤشرات الحيوية الإلتهابيه في السيرم و مستوى resistin بينما يزيد بشكل ملحوظ من مستوي adiponectin في السيرم ، علاوة علي ذلك ، تم تنظيم التعبير الجيني لمستقبلات فيتامين د في أنسجة الكبد وزيادة نسبة فيتامين د في السيرم بشكل ملحوظ مما أدى إلي تحسن مقاومة الانسولين وتقليل نسبة الدهون في السيرم . تظهر النتائج المجهرية وجود إرتشاح دهني بينما بعد تناول فيتامين د حدث تحسن في أنسجة الكبد .

الكلمات المفتاحية: محور الهيبسيدين- فيروبورتين, توازن الحديد , المتلازمة الايضيه , فيتامين د , مستقبلات فيتامين د .